



AUDITORIUM

10.30 **SIMPOSIO 1: LE VIE DI ACCESSO NELLE PROTESI PRIMARIE**
12.00 Moderatori: **Vincenzo Salini** (Milano), **Giovanni Zatti** (Monza)
Anchorman: **Francesco Benazzo** (Pavia)

10.30 LE OPINIONI E I DETTAGLI TECNICI: COME E PERCHÉ
11.05 Via anteriore diretta - **Dante Dallari** (Bologna)
Via antero laterale - **Roberto Civinini** (Firenze)
Via postero laterale - **Giandomenico Logroscino** (L'Aquila)



- 10.30** Set-up: letto chirurgico, posizione del paziente e supporti
10.36 **Dante Dallari** (2'),
Roberto Civinini (2'),
Giandomenico Logroscino (2')
- 10.36** Esposizione acetabolare: circonferenziale o buco della serratura?
10.42 **Dante Dallari** (2'),
Roberto Civinini (2'),
Giandomenico Logroscino (2')
- 10.42** Esposizione femore prossimale: risparmio trocanterico e abduttori,
10.51 accesso e preparazione canale midollare
Dante Dallari (3'),
Roberto Civinini (3'),
Giandomenico Logroscino (3')
- 10.51** Verifica intraoperatoria lunghezza e offset
10.57 **Dante Dallari** (2'),
Roberto Civinini (2'),
Giandomenico Logroscino (2')
- 10.57** Amplificatore di brillantezza: no, sì e come
10.59 **Dante Dallari** (30"),
Roberto Civinini (30"),
Giandomenico Logroscino (30")
- 10.59** Sutura capsulare (no, sì e come)
11.02 **Dante Dallari** (1'),
Roberto Civinini (1'),
Giandomenico Logroscino (1')
- 11.02** Regime e restrizioni post operatorie immediate (no, sì e quali)
11.05 **Dante Dallari** (1'),
Roberto Civinini (1'),
Giandomenico Logroscino (1')

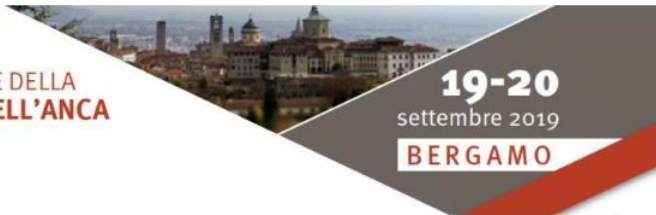19 SETTEMBRE 2019
GIOVEDÌ

- 11.05** La via laterale diretta: è ancora attuale?
11.12 **Filippo Casella** (Roma)
- 11.12** Discussione
11.35
- FATTI, IPOTESI E ILLUSIONI**
- 11.35** L'informazione al paziente: chi, come
11.45 **Luigi Zagra** (Milano)
- 11.45** La letteratura e i registri: sopravvivenza, complinanze
11.55 e risultati a medio lungo termine
Emilio Romanini (Roma)
- 11.55** Fate quello che fate bene... ma fatelo molto bene
12.00 **Francesco Benazzo** (Pavia)





CONGRESSO NAZIONALE DELLA
SOCIETÀ ITALIANA DELL'ANCA



LE VIE DI ACCESSO NELLE PROTESI PRIMARIE LE OPINIONI E I DETTAGLI TECNICI: COME E PERCHÉ

VIA ANTERIORE: D. Dallari

VIA ANTERO LATERALE: R. Civinini

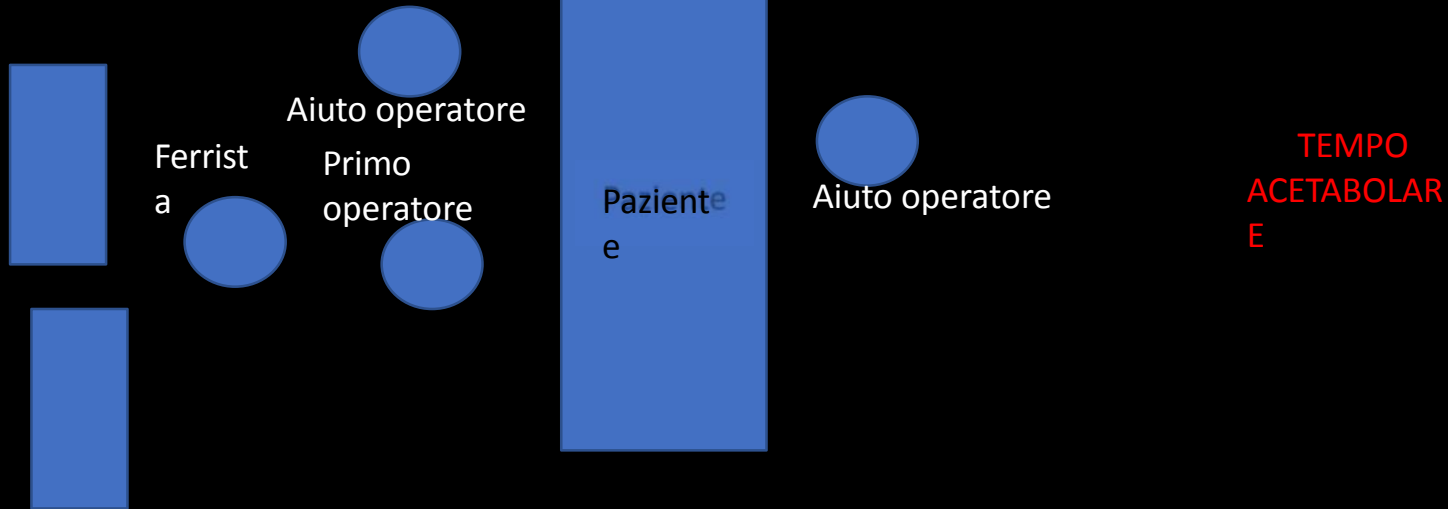
VIA POSTERO LATERALE: G. Logroscino

Set-up: Letto chirurgico,
posizione del paziente e supporti

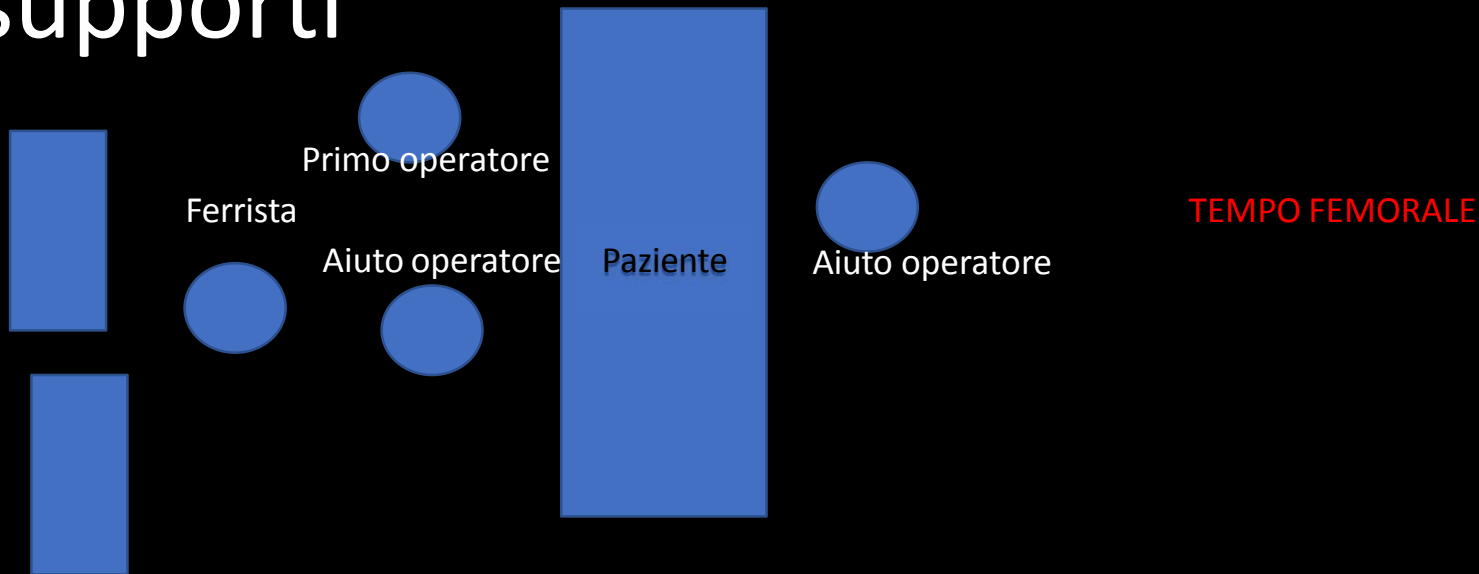
Set-up: Letto chirurgico, posizione del paziente e supporti



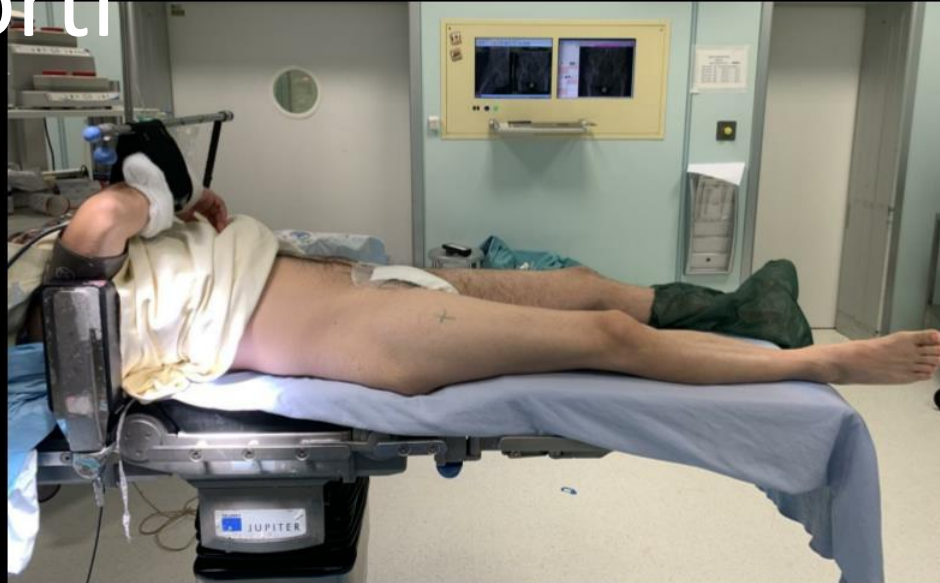Set-up: Letto chirurgico, posizione del paziente e supporti



Set-up: Letto chirurgico, posizione del paziente e supporti

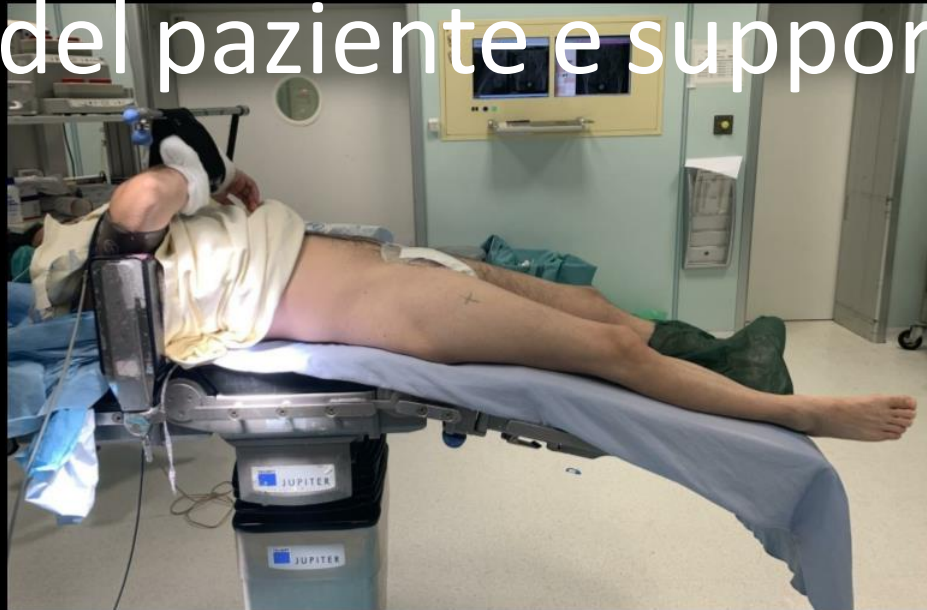

Set-up: Letto chirurgico, posizione del paziente e supporti



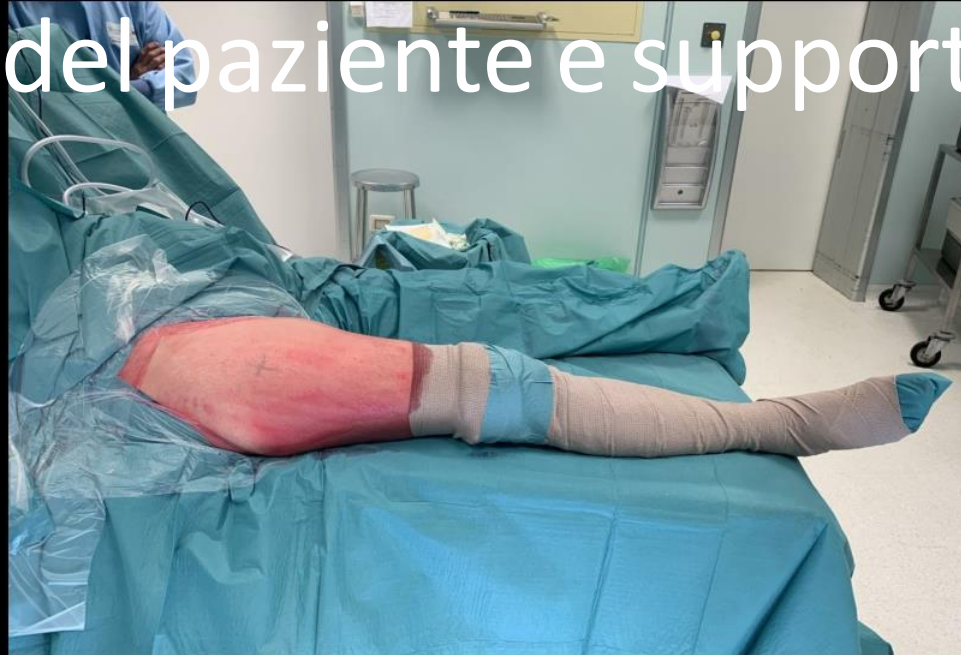Set-up: Letto chirurgico,
posizione

del paziente e supporti



Set-up: Letto chirurgico, posizione

del paziente e supporti



Set-up: Letto chirurgico, posizione del paziente e supporti

Review

W J Am Acad Orthop Surg. 2014 Sep;22(9):595-603. doi: 10.5435/JAAOS-22-09-595.

Direct anterior approach for total hip arthroplasty: indications, technique, and results.

Post ZD, Orozco F, Diaz-Ledezma C, Hozack WJ, Ong A.

L'uso di strumentari dedicati e letto da trazione determina una più veloce Learning curve, anche se risulta più difficile la valutazione intraoperatoria di offset e dismetria


J Orthop Surg Res. 2019 Jul 16;14(1):218. doi: 10.1186/s13018-019-1272-0.

Adopting the direct anterior approach: experience and learning curve in a Chinese patient population.

Kong X¹, Grau L², Ong A², Yang C³, Chai W⁴.

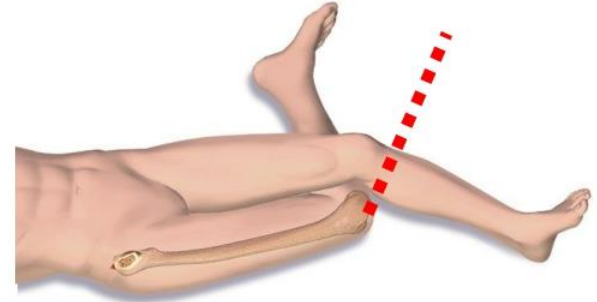
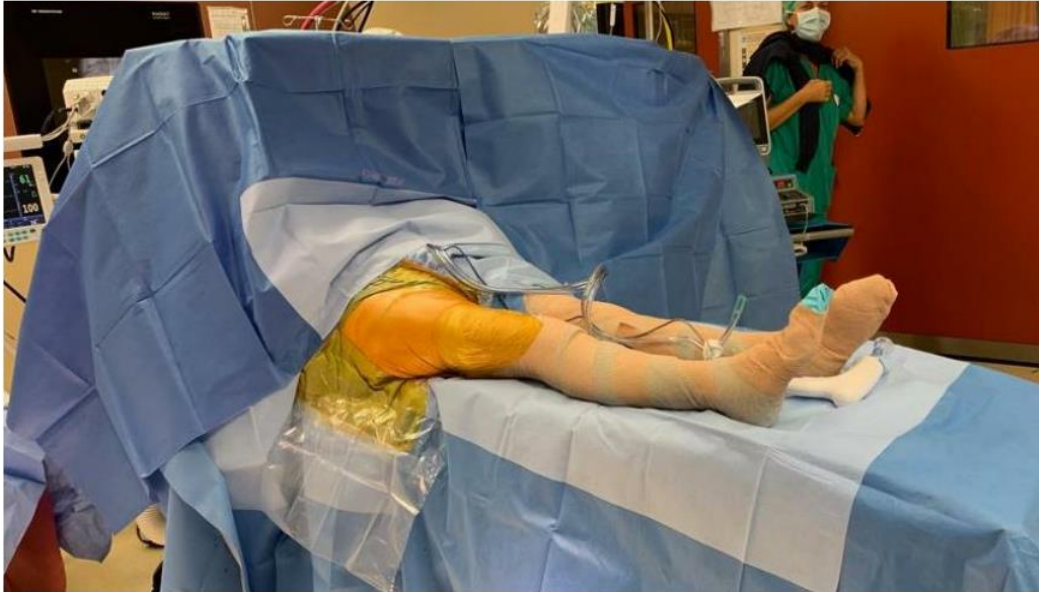RESULTS: There was a significant decrease in the complication rate from 44% in the first 50 cases to 16% in the second 50.

Via Antero-laterale: Letto chirurgico



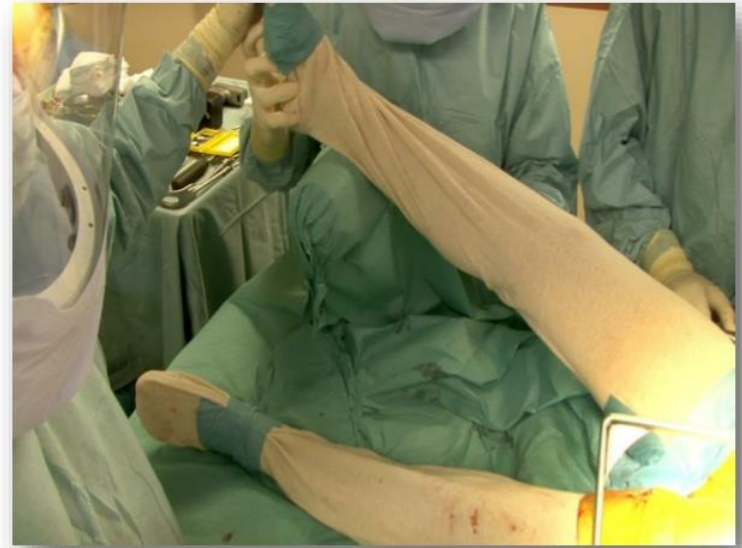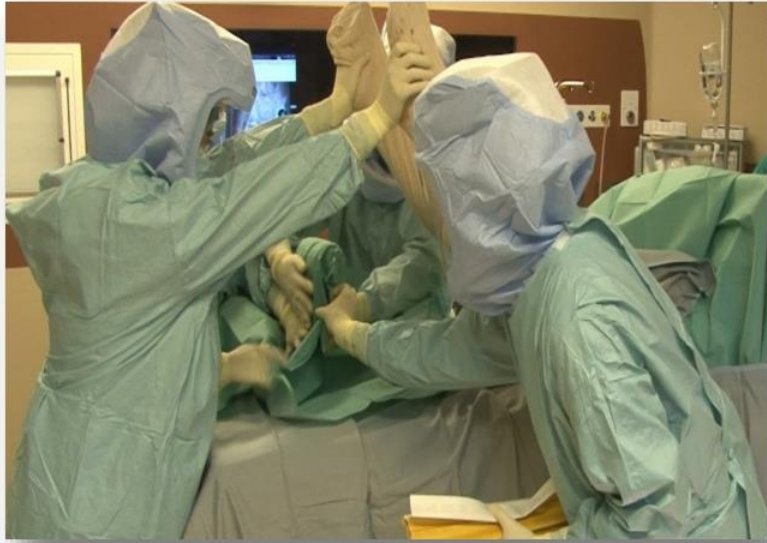La via antero-laterale viene eseguita
con un letto operatorio standard

Via Antero-laterale: Posizione del paziente



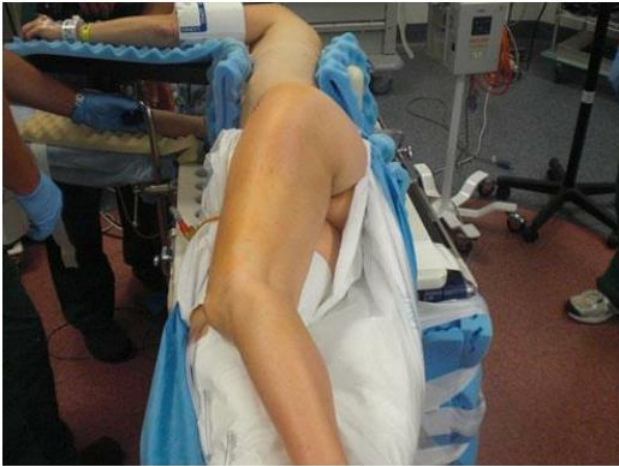Paziente in posizione supina.
Ambidue gli arti inferiori vengono preparati sterili

Via Antero-laterale: Supporti

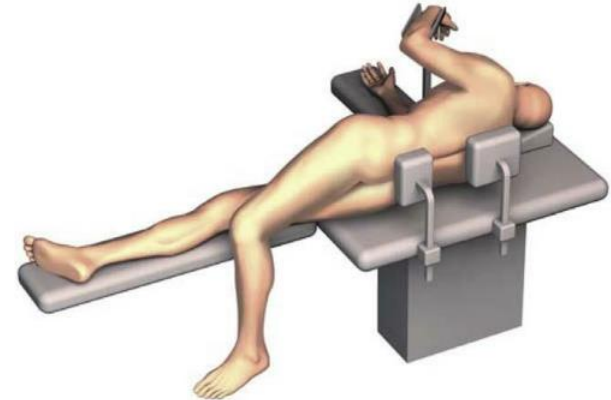
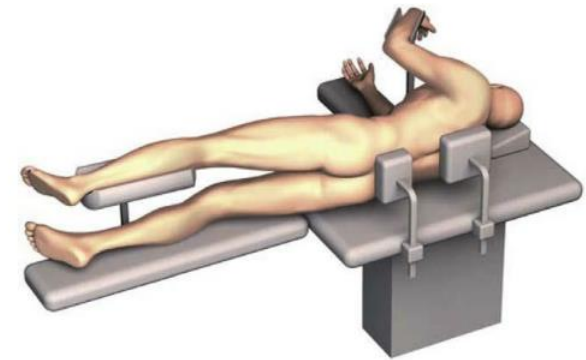


Un supporto alla base del letto viene incluso nel campo operatorio

Via Antero-laterale: Posizione del paziente



Paziente in decubito laterale.



Posizionando l'arto durante la preparazione femorale in estensione, adduzione e 90° di extra-rotazione.



CONGRESSO NAZIONALE DELLA
SOCIETÀ ITALIANA DELL'ANCA

19-20
settembre 2019
BERGAMO

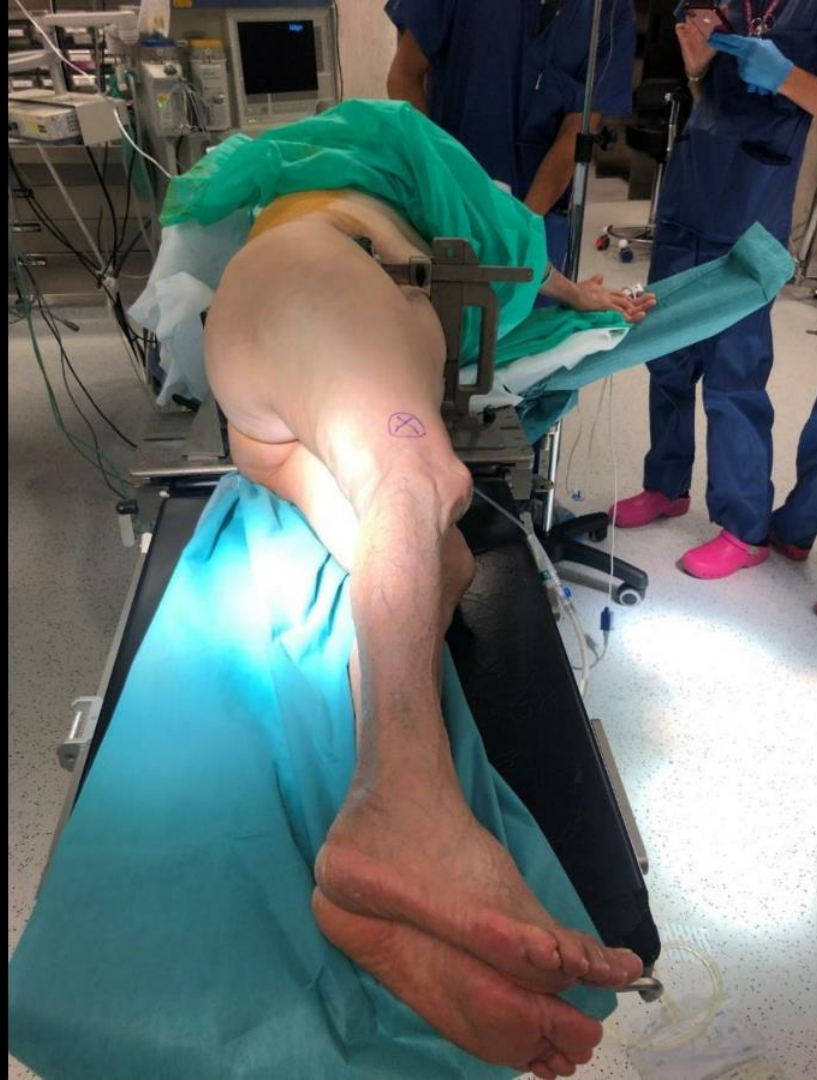LA VIA POSTERO LATERALE

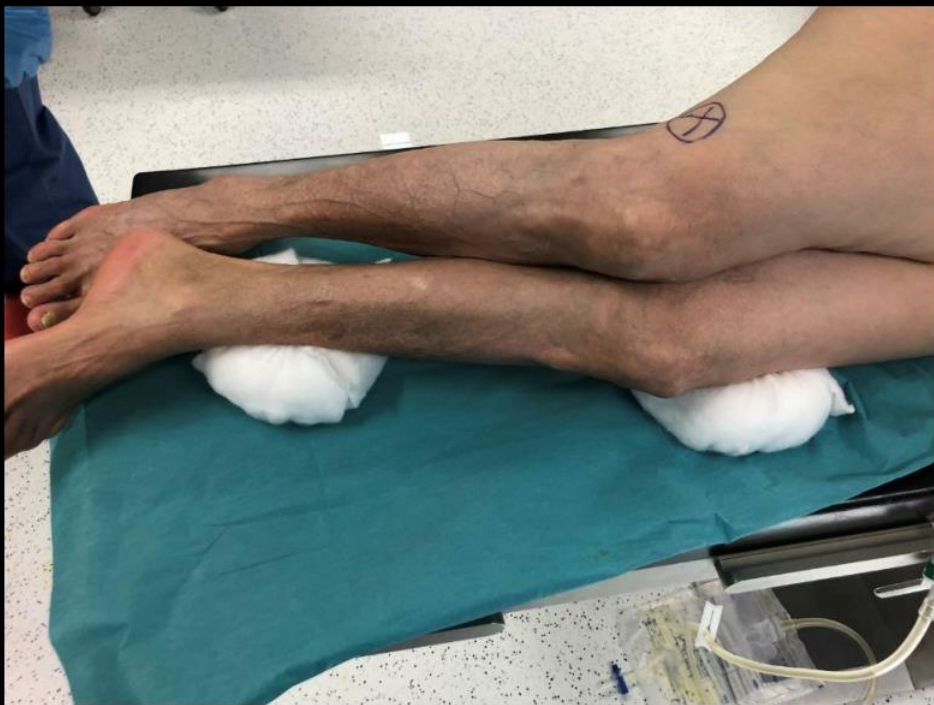SET-UP:

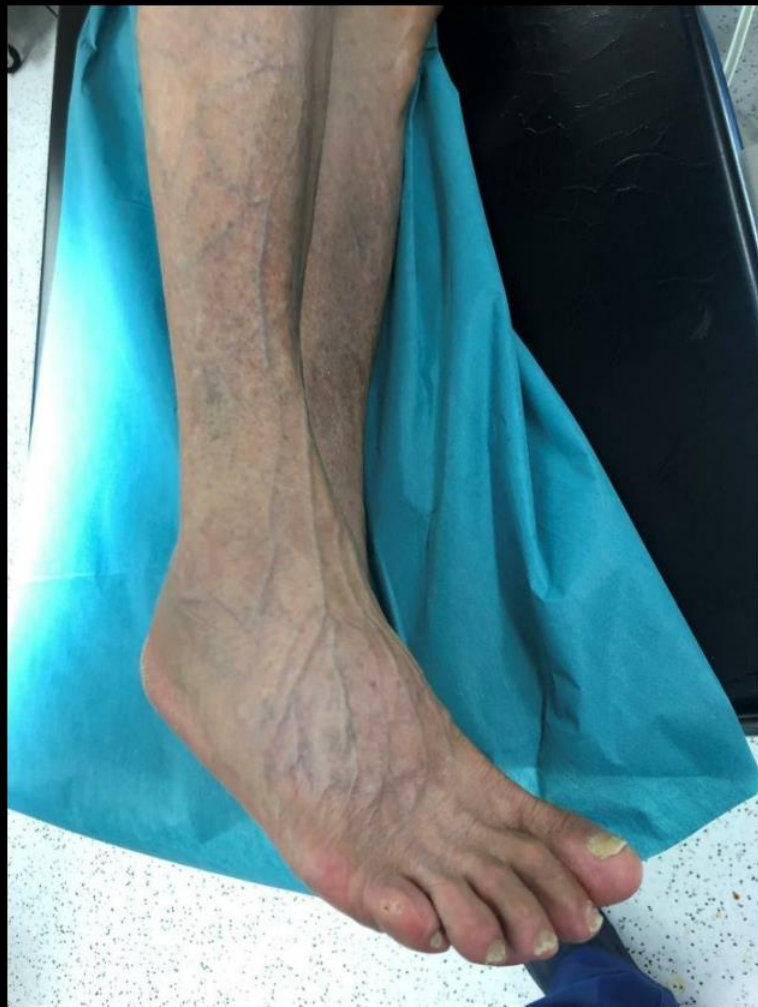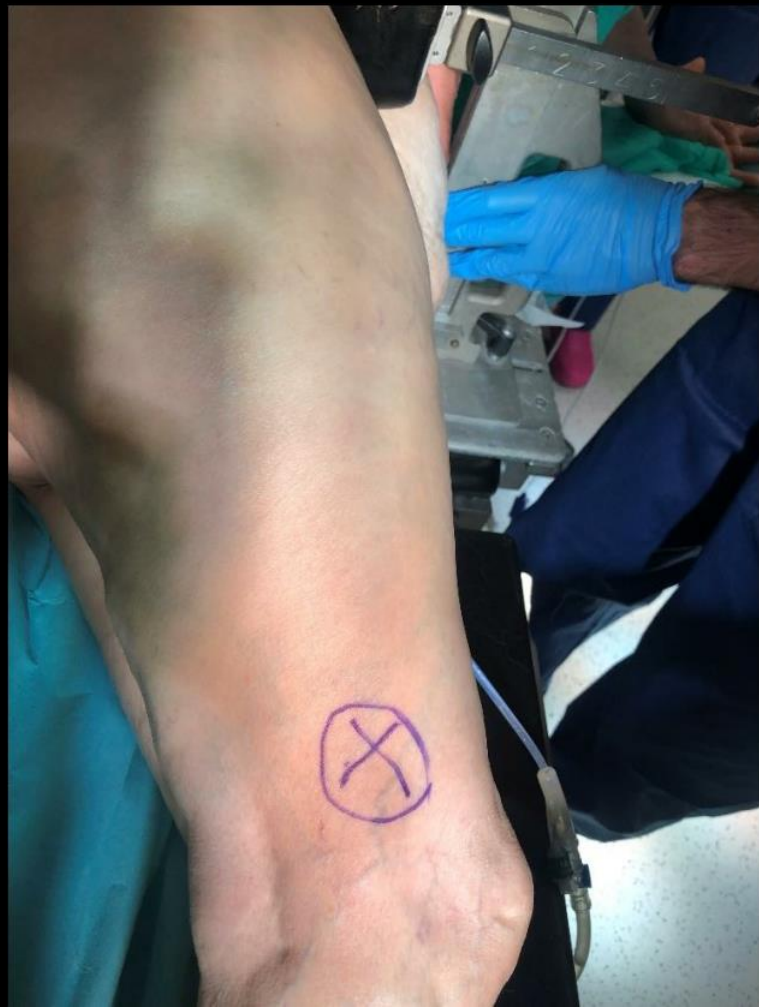Letto chirurgico, Posizione del paziente e Supporti

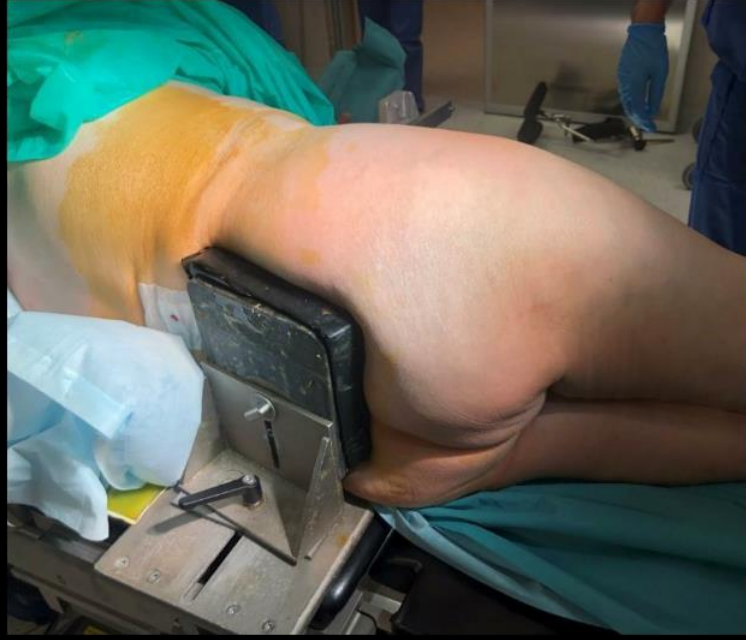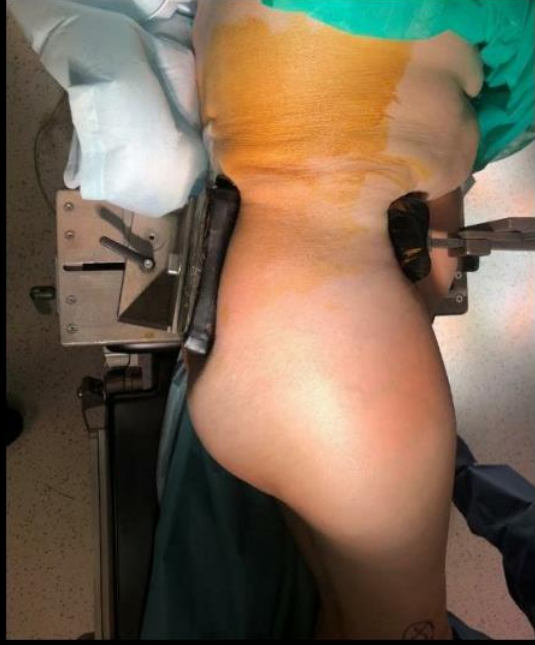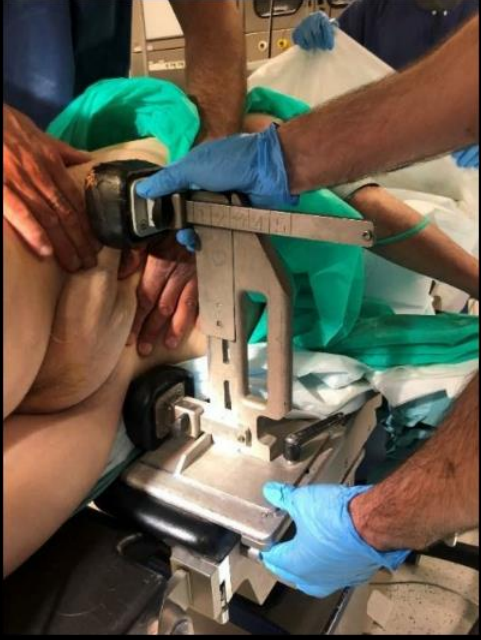Giandomenico Logroscino

*Chirurgia Mininvasiva e Computer Assistita
Università dell'Aquila, Ospedale San Salvatore Asl 1 Abruzzo
Direttore: Prof. V. Calvisi*



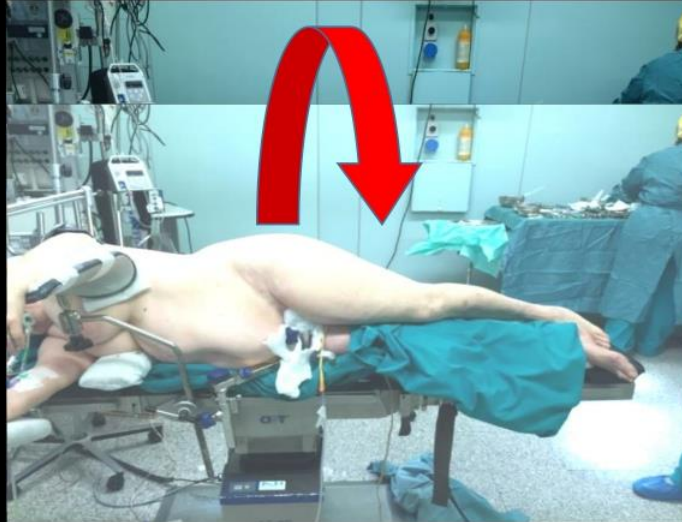





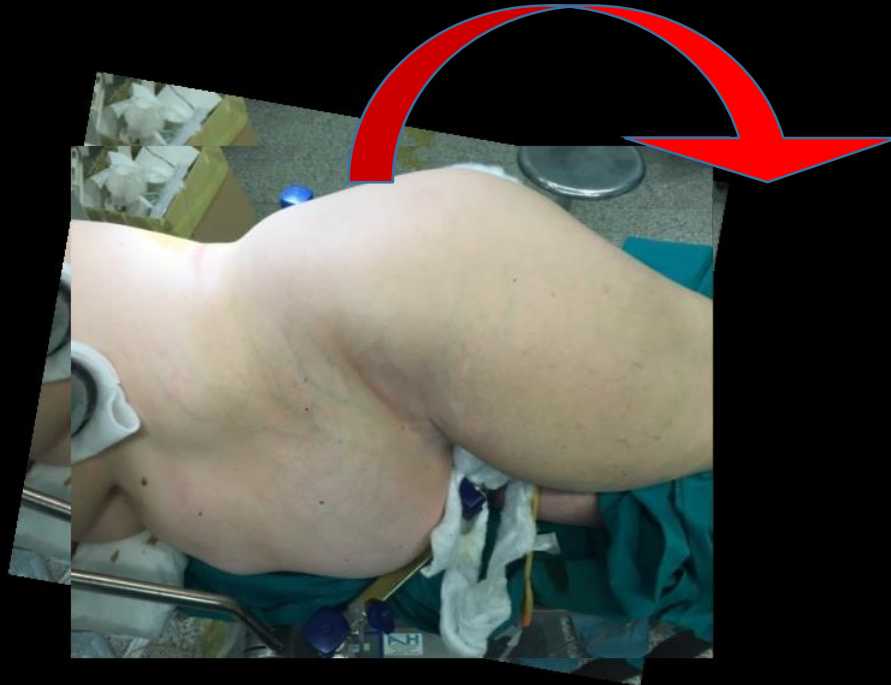ALTRE OPZIONI

Pressore Anteriore Singolo (Pubico)



ATTENZIONE!

Pazienti Obesi



Cosa Dice La Letteratura.....

The Journal of Arthroplasty 33 (2018) 3496–3501



Contents lists available at ScienceDirect

The Journal of Arthroplasty

journal homepage: www.arthroplastyjournal.org



Primary Arthroplasty

Variability of Pelvic Orientation in the Lateral Decubitus Position:
Are External Alignment Guides Trustworthy?



Jesse E. Otero, MD, PhD^{a,b,*}, Keith A. Fehring, MD^a, John R. Martin, MD^a,
Susan M. Odum, PhD^a, Thomas K. Fehring, MD^a

^a OrthoCarolina, Hip and Knee Center, Charlotte, NC

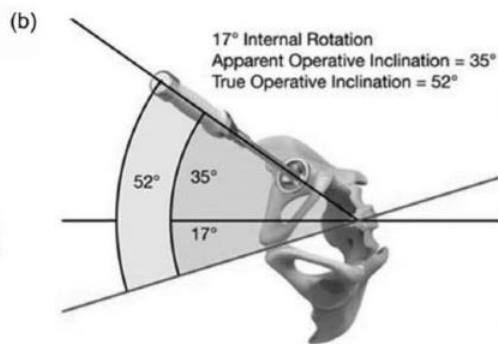
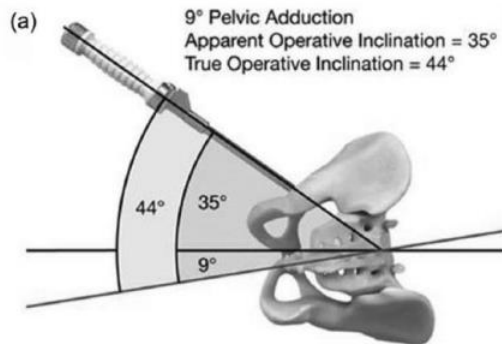
^b Department of Orthopedics and Rehabilitation, The University of Iowa Hospitals and Clinics, Iowa City, IA

38% of patients in the lateral decubitus position were malpositioned in tilt, rotation, or

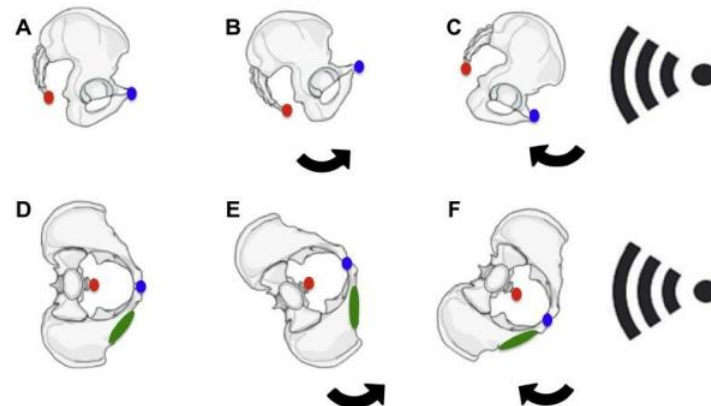
both

INCLINATO VERSO I PIEDI = COTILE VERTICALE

APPANCIATO = COTILE VERTICALE ($>10^\circ$) RETROVERSO



J.E. Otero et al. / The Journal of Arthroplasty 33 (2018) 3496–3501



Rutherford, Hip International 2019

Patient positioning and cup orientation during total hip arthroplasty: assessment of current UK practice

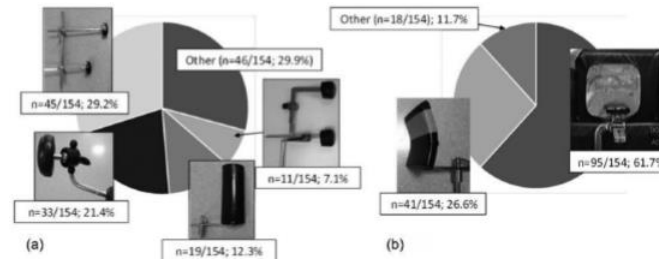
HIP International
2019, Vol. 29(1) 89–95
© The Author(s) 2018
Article reuse guidelines:
sagepub.com/journals-permissions
DOI: 10.1177/1120700018760818
journals.sagepub.com/home/hpi
SAGE

Megan Rutherford¹, John D O'Connor¹, Janet C Hill²,
David E Beverland², Alex B Lennon¹ and Nicholas J Dunne^{3–7}

44% of orthopaedic surgeons in the UK
used 2 anterior superior iliac spine supports

Grammatopoulos et al (*Bone Joint J.* 2014)

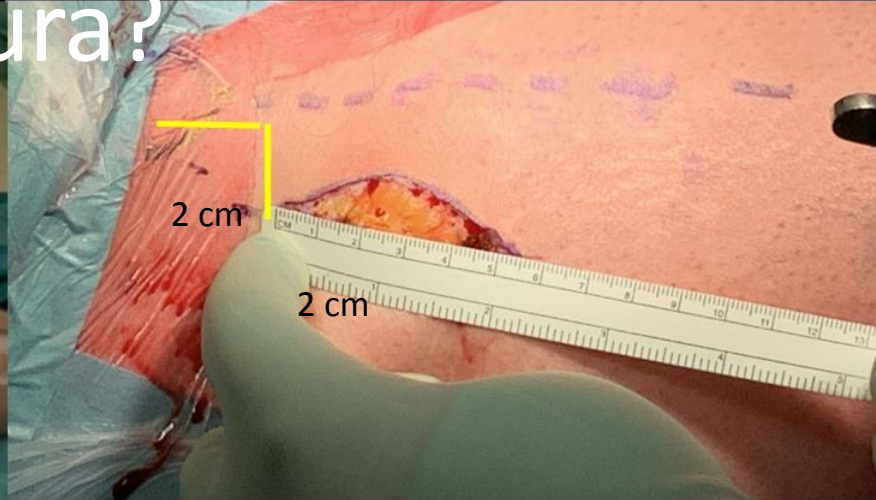
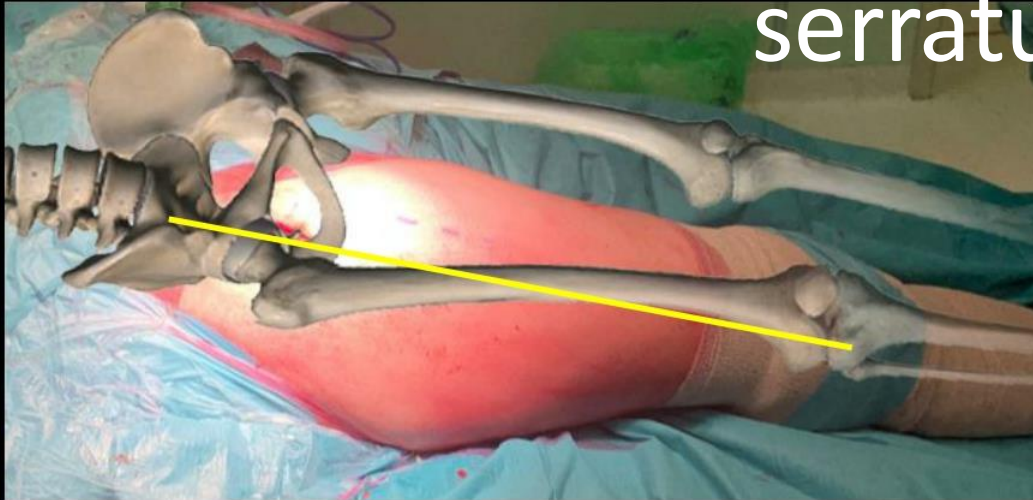
demonstrated that the use of 2 anterior superior iliac spine supports
reduced intraoperative pelvic movement when compared to a single anterior superior iliac spine brace-
arm



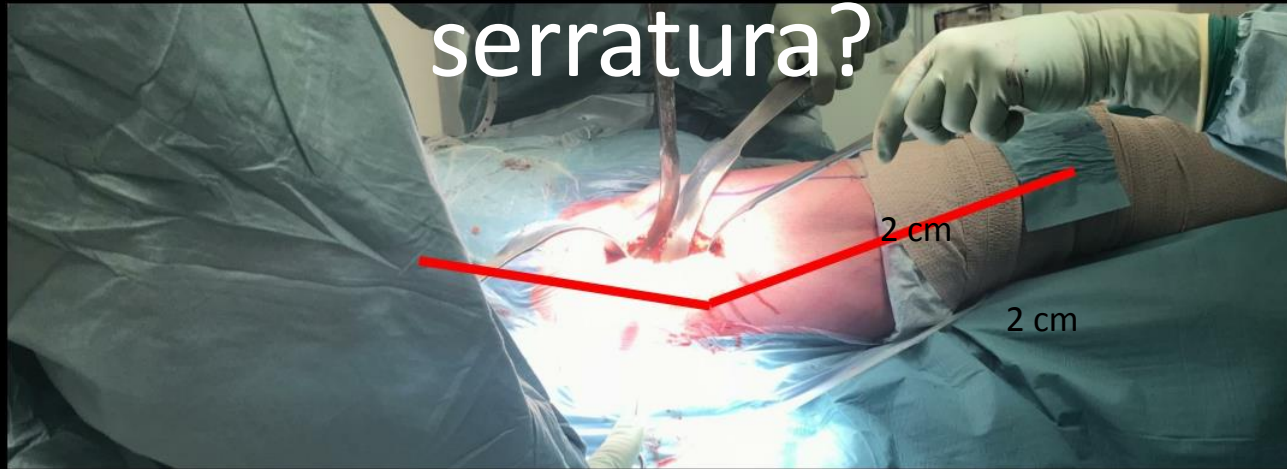Esposizione acetabolare:
circonferenziale o buco della
serratura?

Esposizione acetabolare: circonferenziale o buco della

serratura?

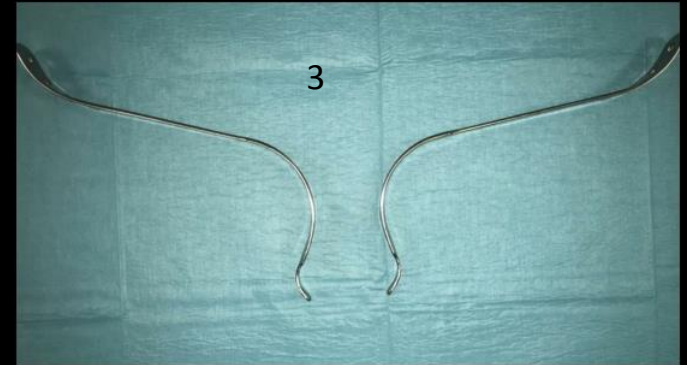
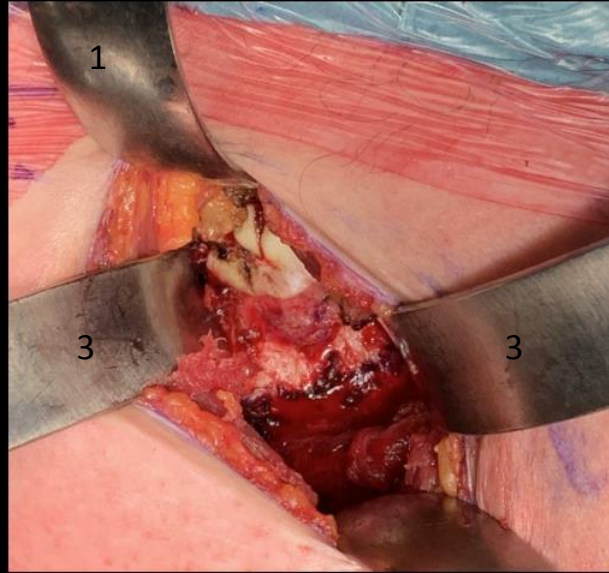
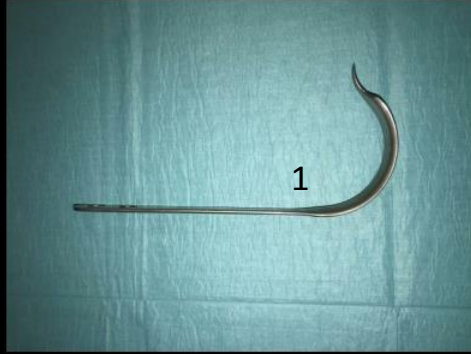

Esposizione acetabolare:
circonferenziale o buco
della



Esposizione acetabolare: circonferenziale o buco della serratura?

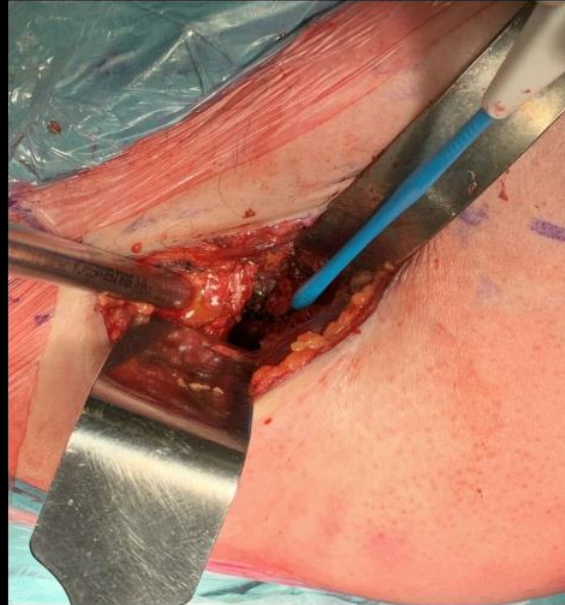
PEARLS AND PITFALLS



Esposizione acetabolare: circonferenziale o buco della serratura?

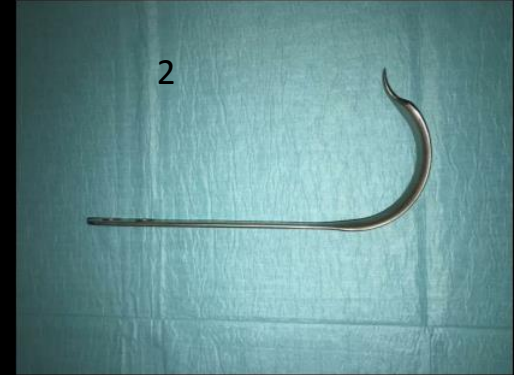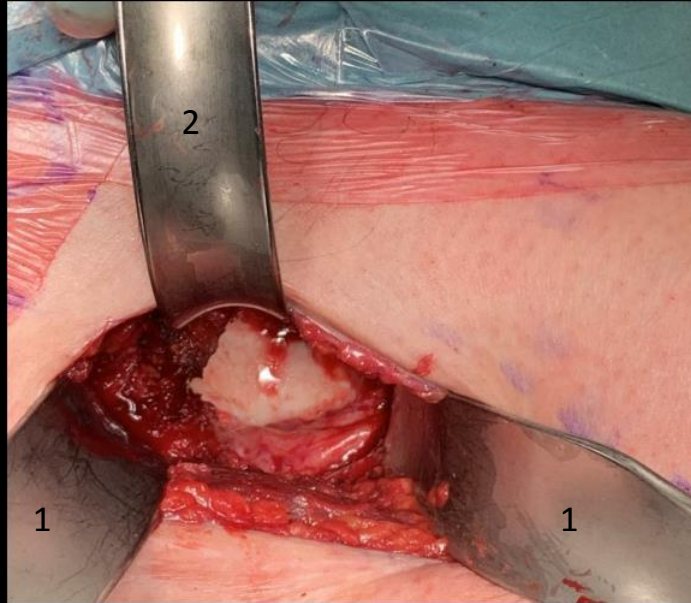
PEARLS AND PITFALLS

2- ESEGUIRE RELEASE CAPSULARE
POSTERIORE, PER FACILITARE LA RIMOZIONE



1- RIMOVERE LE LEVE
E MANTENERE SOLO
SPATOLA AD ANCA PER
PROTEGGERE VENTRE
MUSCOLARE DEL
TENSORE FASCIA LATA,
DURANTE LA
RIMOZIONE DELLA
TESTA FEMORALE

Esposizione acetabolare: circonferenziale o buco della serratura?

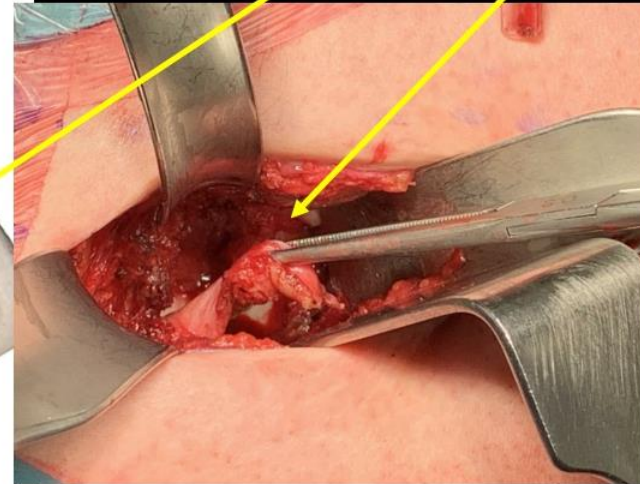
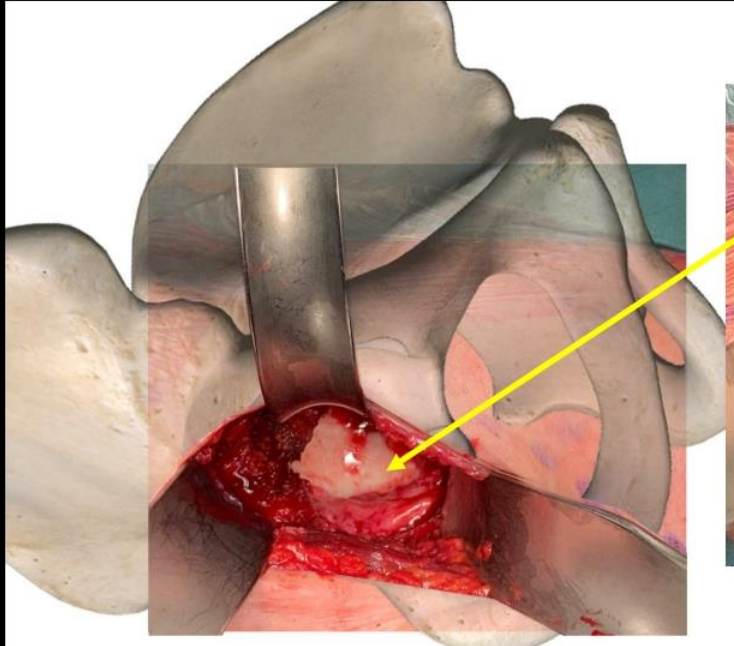


Esposizione acetabolare: circonferenziale o buco della serratura?

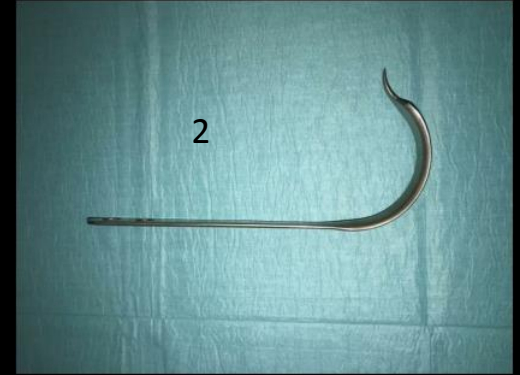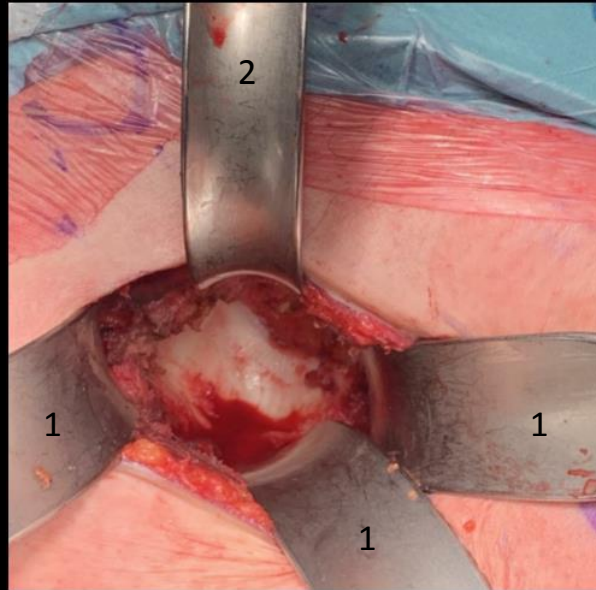
PEARLS AND PITFALLS

Rimozione legamento orbicolare e labrum

residuo



Esposizione acetabolare: circonferenziale o buco della ~~serratura~~?

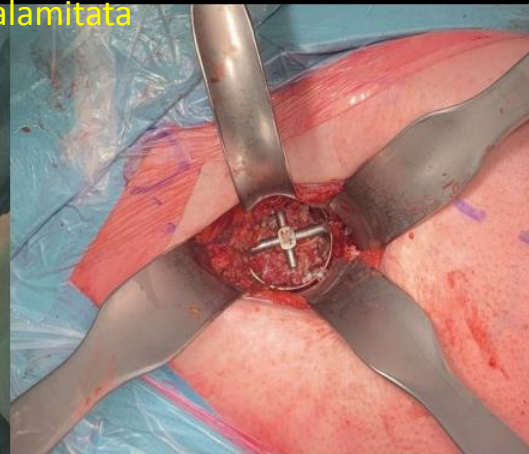
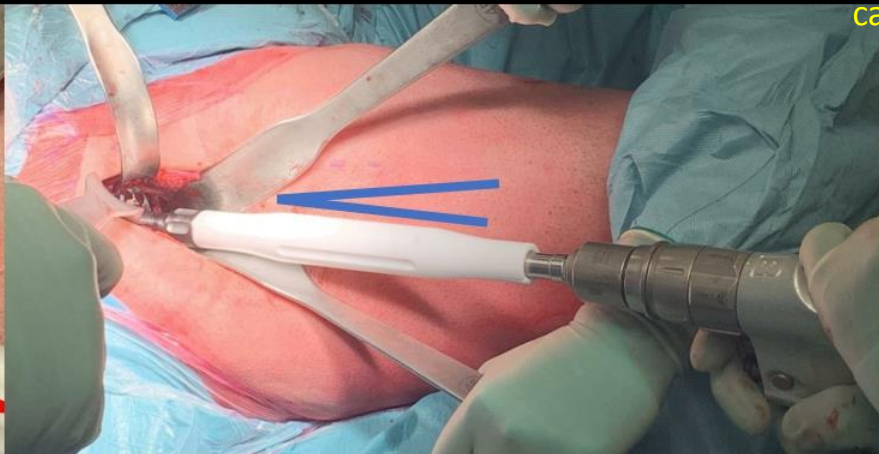
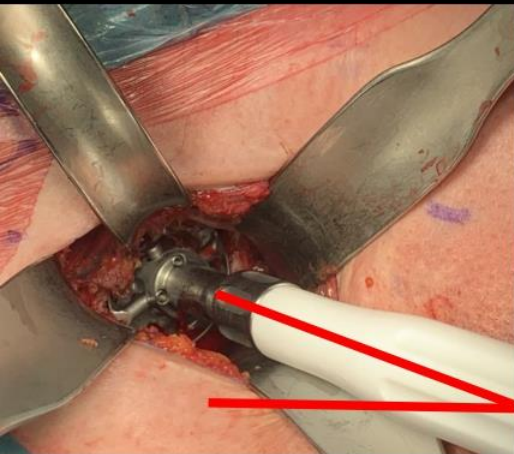


Esposizione acetabolare: circonferenziale o buco della serratura?

PEARLS AND PITFALLS

Fresa

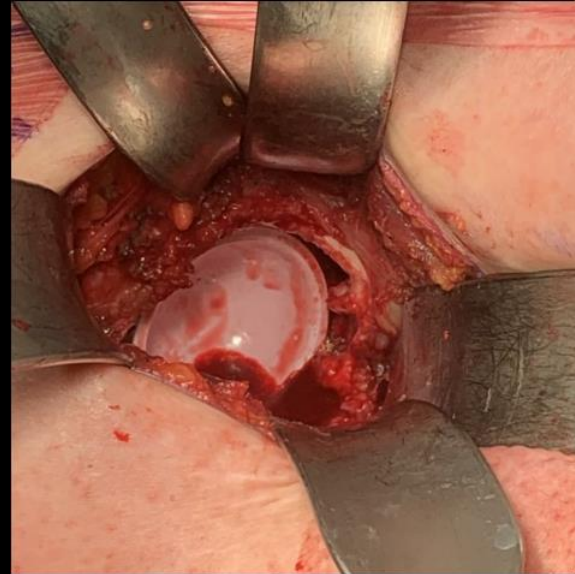
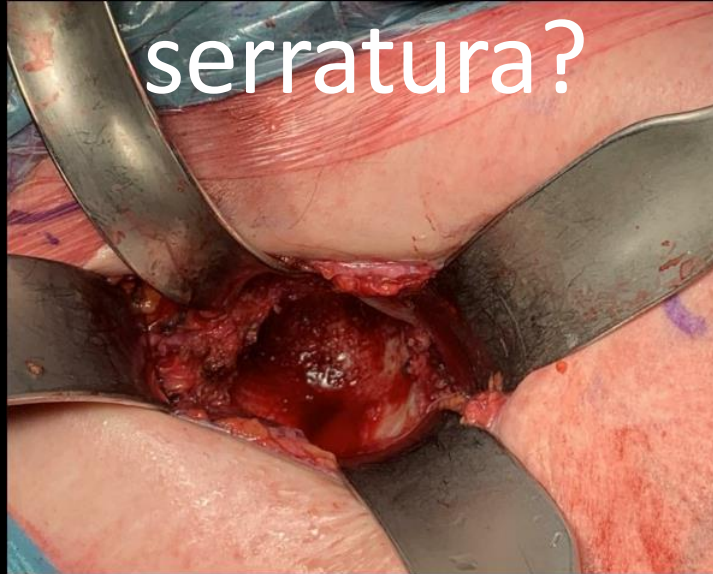
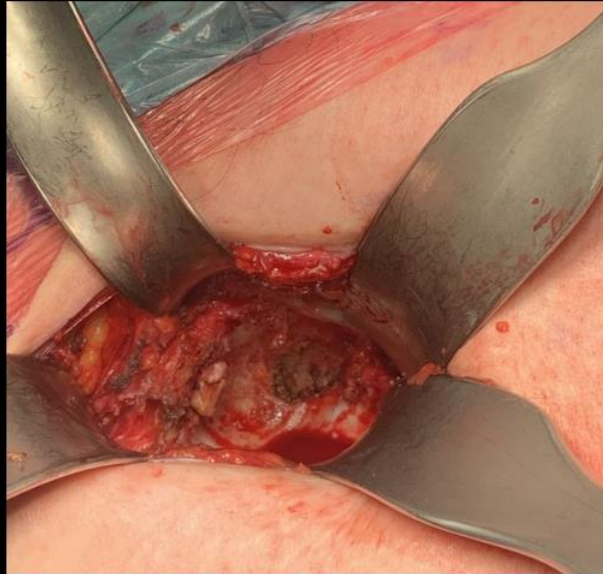
calamitata



Landmark: legamento trasverso

Esposizione acetabolare: circonferenziale o buco della

serratura?



Esposizione acetabolare: circonferenziale o buco della serratura?

Review

J Bone Joint Surg Am. 2016 Sep 7;98(17):e72. doi: 10.2106/JBJS.15.01080.

Surgeons' Accuracy in Achieving Their Desired Acetabular Component Orientation.

Grammatopoulos G¹, Alvand A², Monk AP², Mellon S³, Pandit H², Rees J², Gill HS⁴, Murray DW².

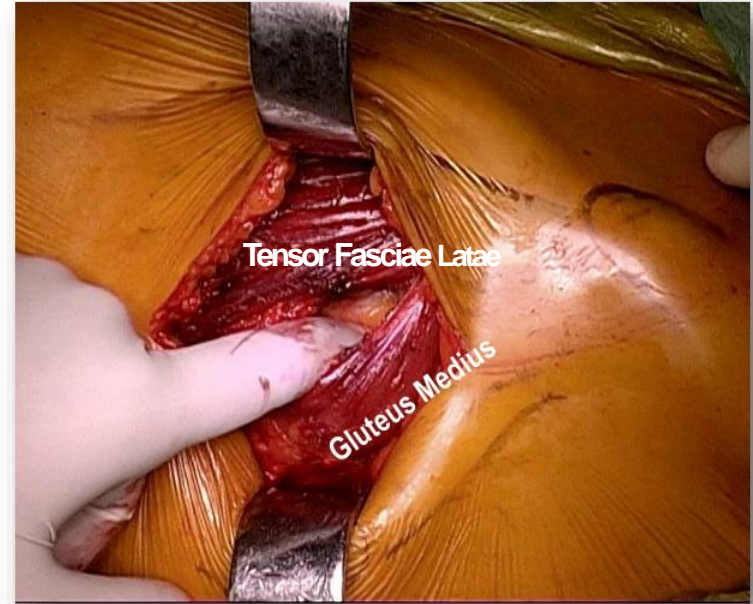
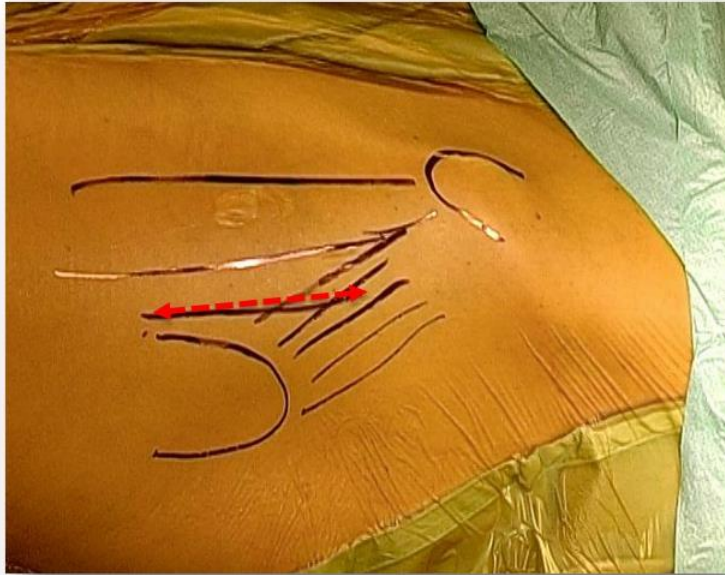
Author information

- 1 Nuffield Orthopaedic Centre, Oxford, United Kingdom Nuffield Department of Orthopaedics, Rheumatology & Musculoskeletal Sciences, Headington, Oxford, United Kingdom george.grammatopoulos@ndorms.ox.ac.uk.
- 2 Nuffield Orthopaedic Centre, Oxford, United Kingdom Nuffield Department of Orthopaedics, Rheumatology & Musculoskeletal Sciences, Headington, Oxford, United Kingdom.
- 3 Nuffield Department of Orthopaedics, Rheumatology & Musculoskeletal Sciences, Headington, Oxford, United Kingdom.
- 4 Department of Mechanical Engineering, University of Bath, Bath, United Kingdom.

L'esperienza del chirurgo è il principale fattore di influenza
del posizionamento della coppa acetabolare in ogni

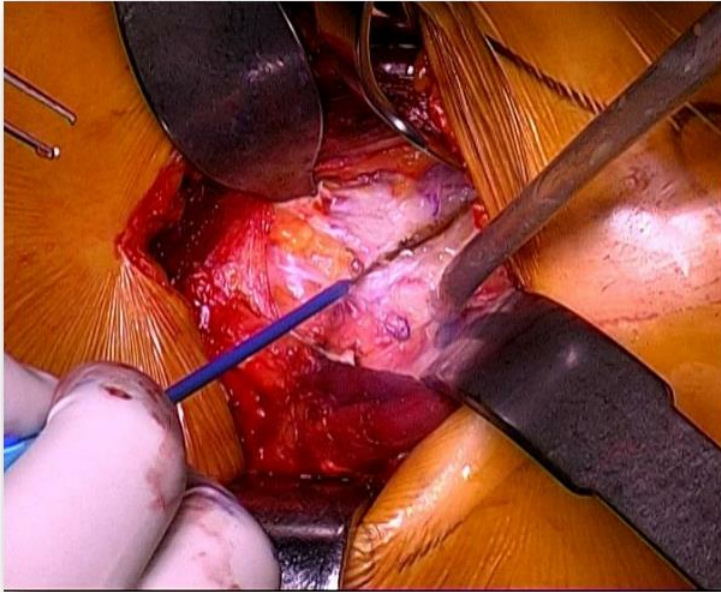
CONCLUSIONS: Surgeons overestimate operative inclination and underestimate anteversion, which is of benefit, as this, on average, helps to achieve the desired radiographic cup orientation. Although the use of visual cues helps, conventional techniques result in a large variability in acetabular component orientation. New and better guides and methods for training need to be developed.

Via Antero-laterale: Esposizione del cotile

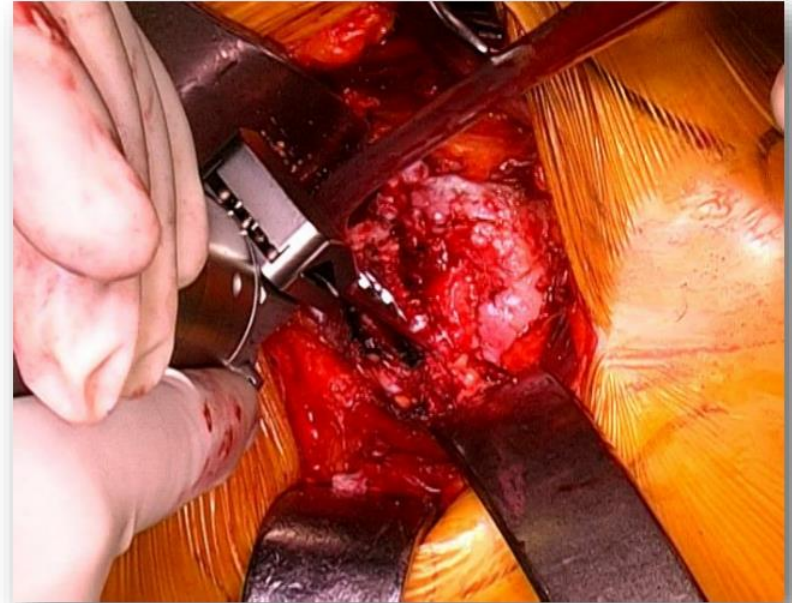


Per via smussa si identifica l'intervallo fra
tensore e medio gluteo.

Via Antero-laterale: Esposizione del cotile

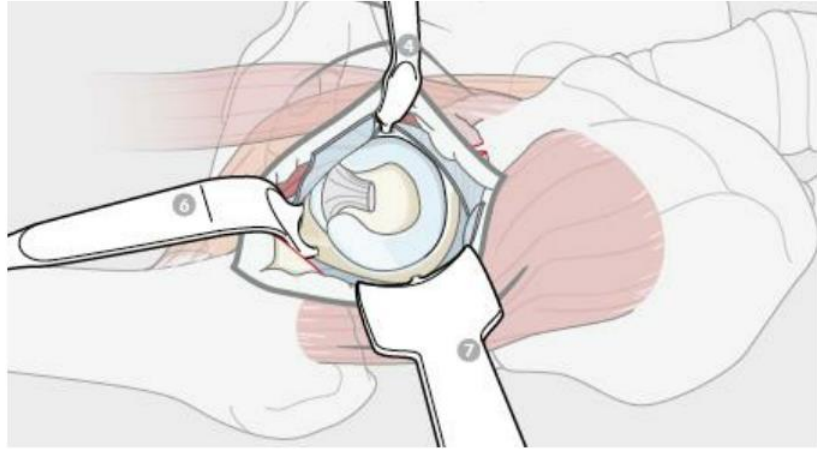


Incisione a T della capsula e capsuletomia anteriore

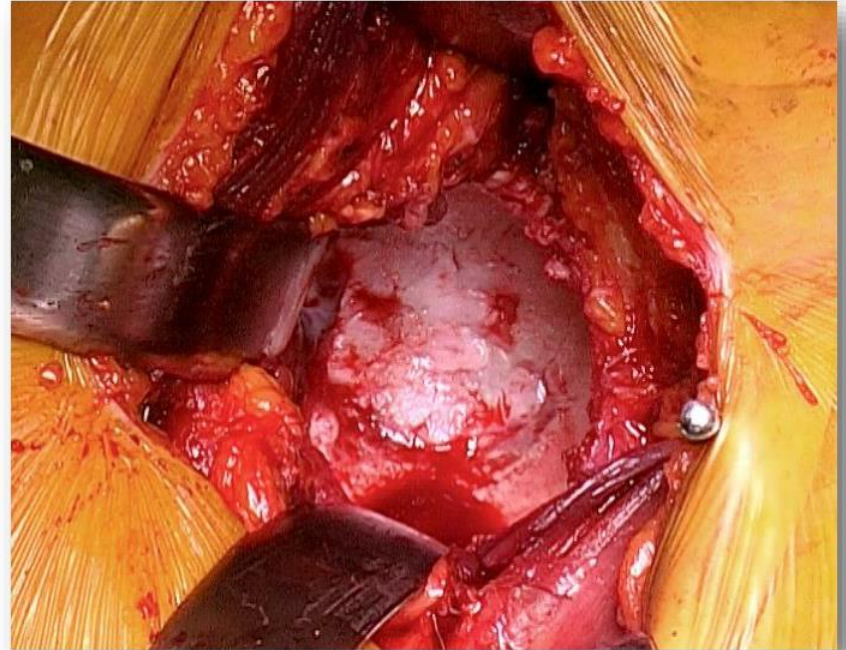

Si esegue quindi l'osteotomia in situ della testa per evitare di danneggiare il medio gluteo

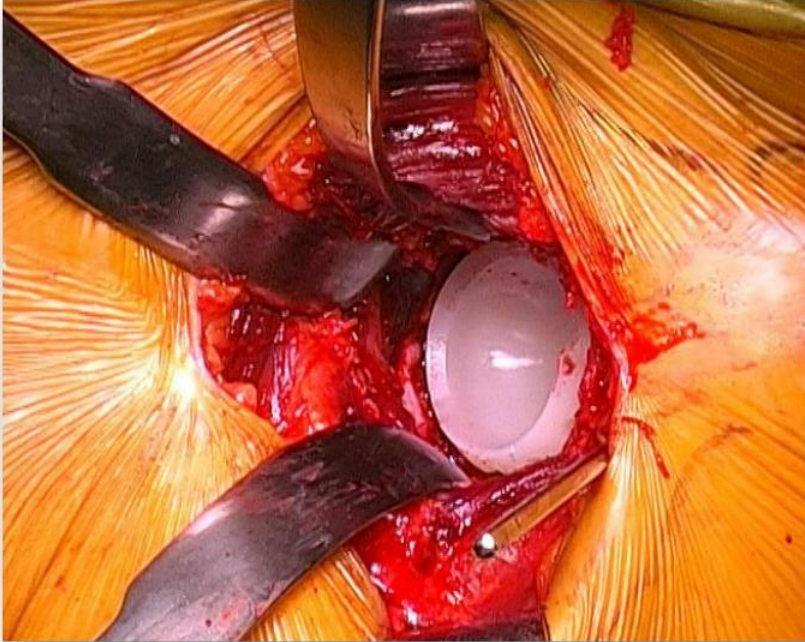
Via Antero-laterale: Esposizione del cotile



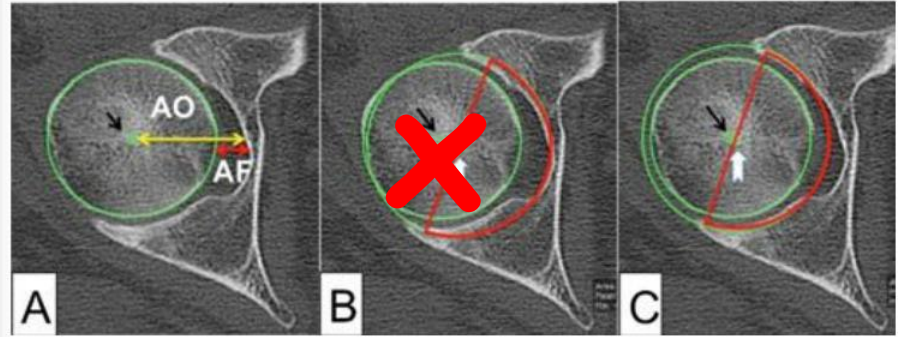
Esposizione circonferenziale
del cotile



Via Antero-laterale: Esposizione del cotile



impingement



This technique:

- Limit the displacement of the CRH
- Improves Hip Range of Motion
- Decreases the risk of bony
- Allow better bone quality

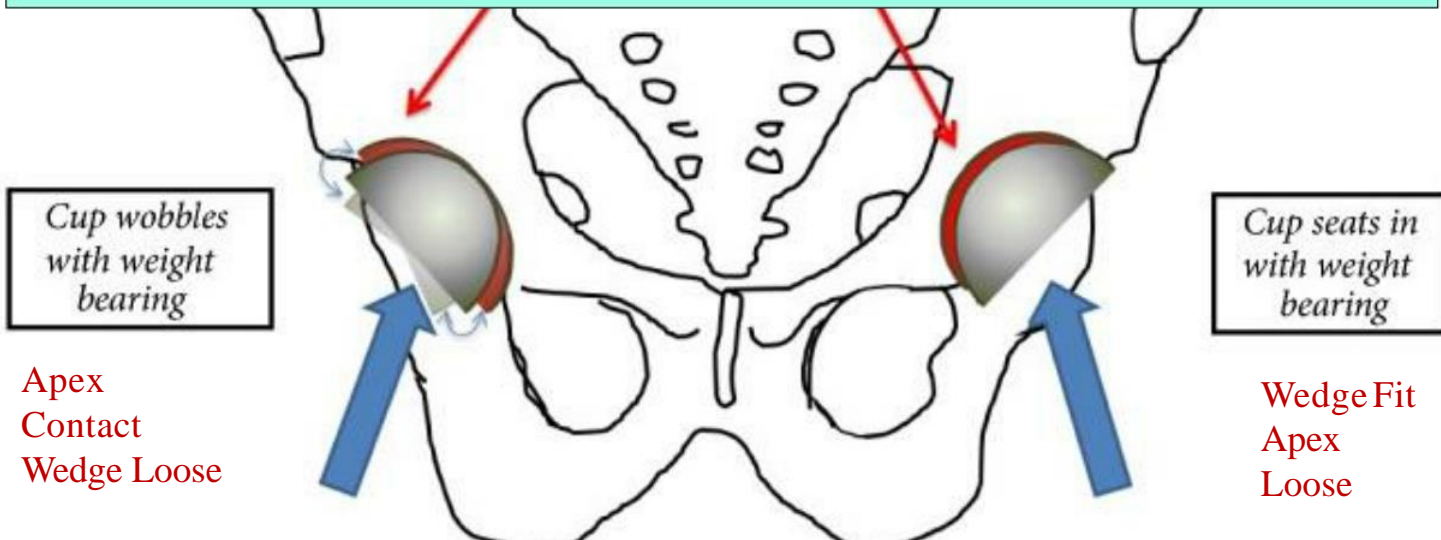


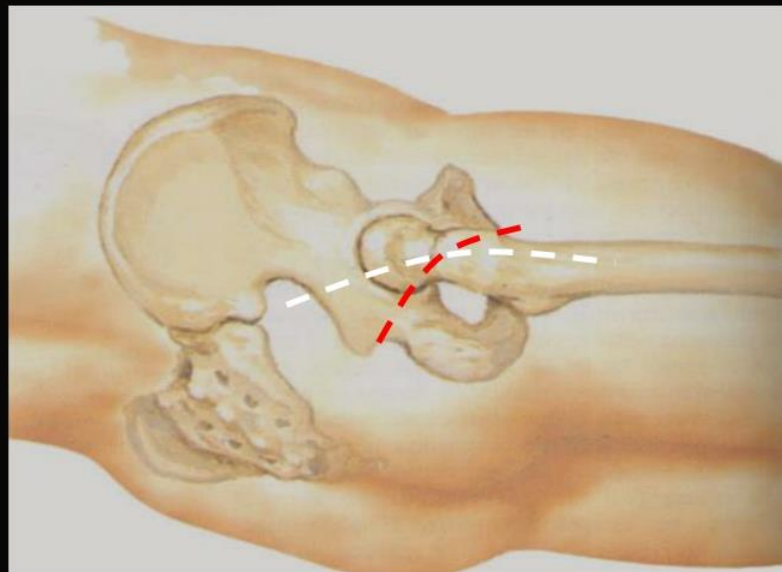
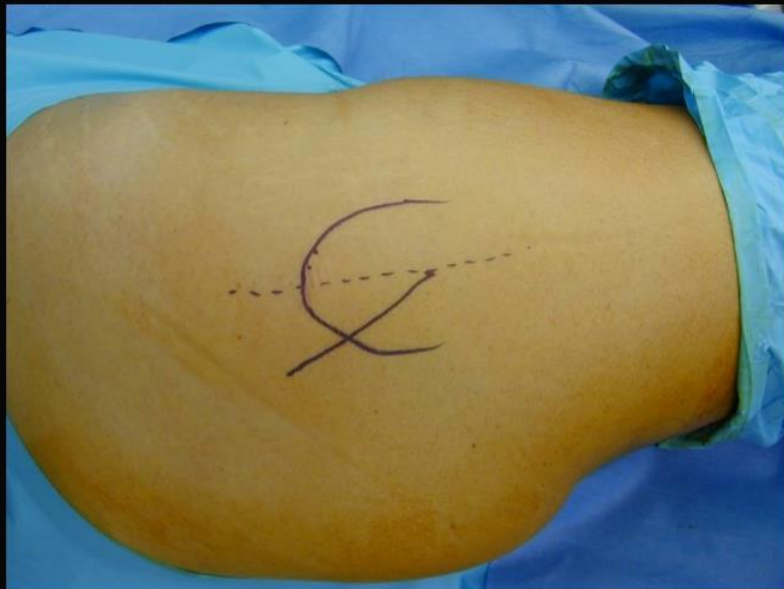CONGRESSO NAZIONALE DELLA
SOCIETÀ ITALIANA DELL'ANCA

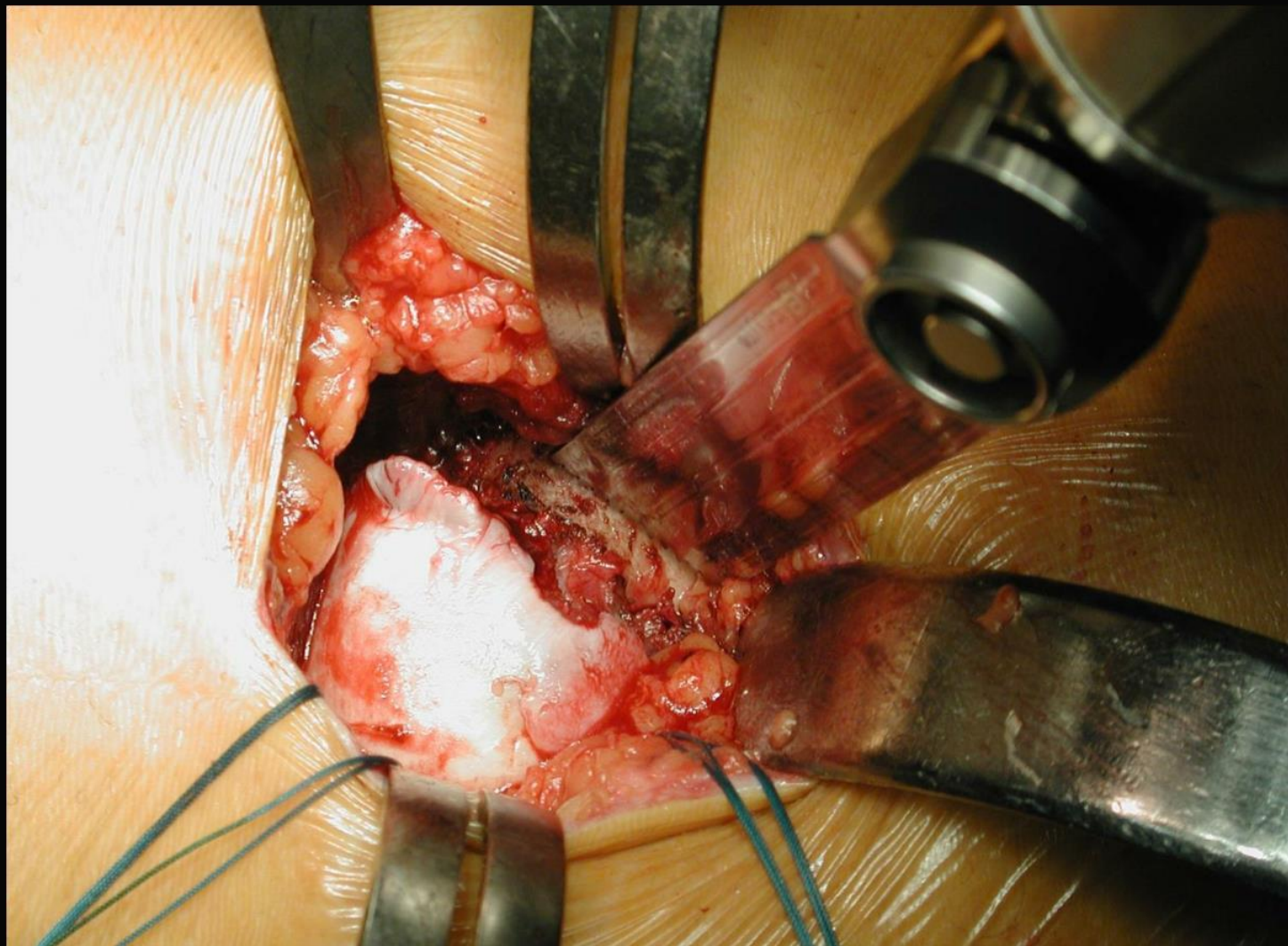
19-20
settembre 2019
BERGAMO

LA VIA POSTERO LATERALE

ESPOSIZIONE ACETABOLARE : Circonferenziale o Buco della serratura?







Anteriore

Posteriore

Inferiore
(Destro o Sinistro)

Wm. Nephew
64-031 03042093



Anteriore

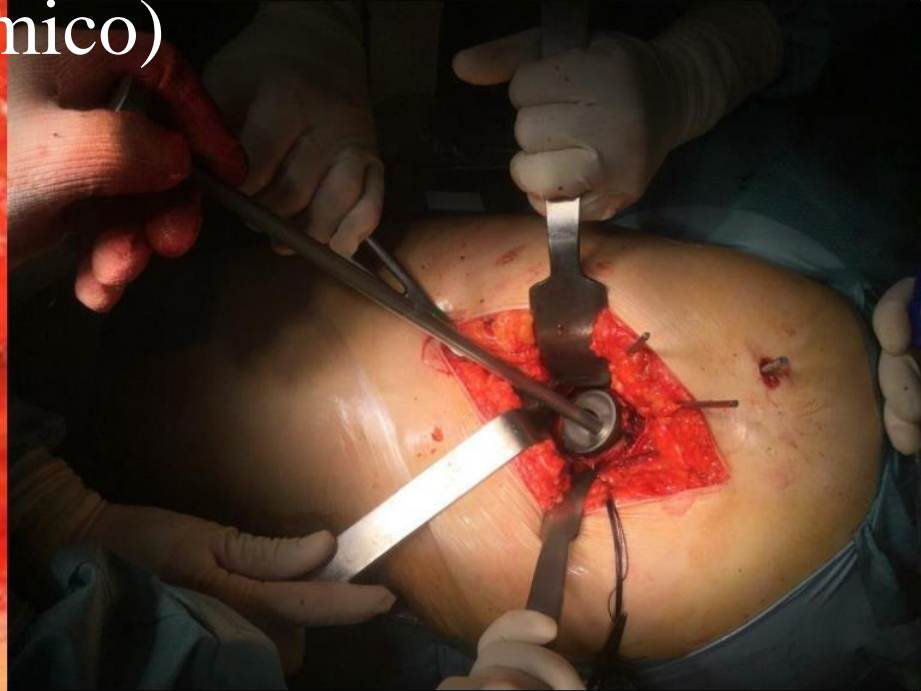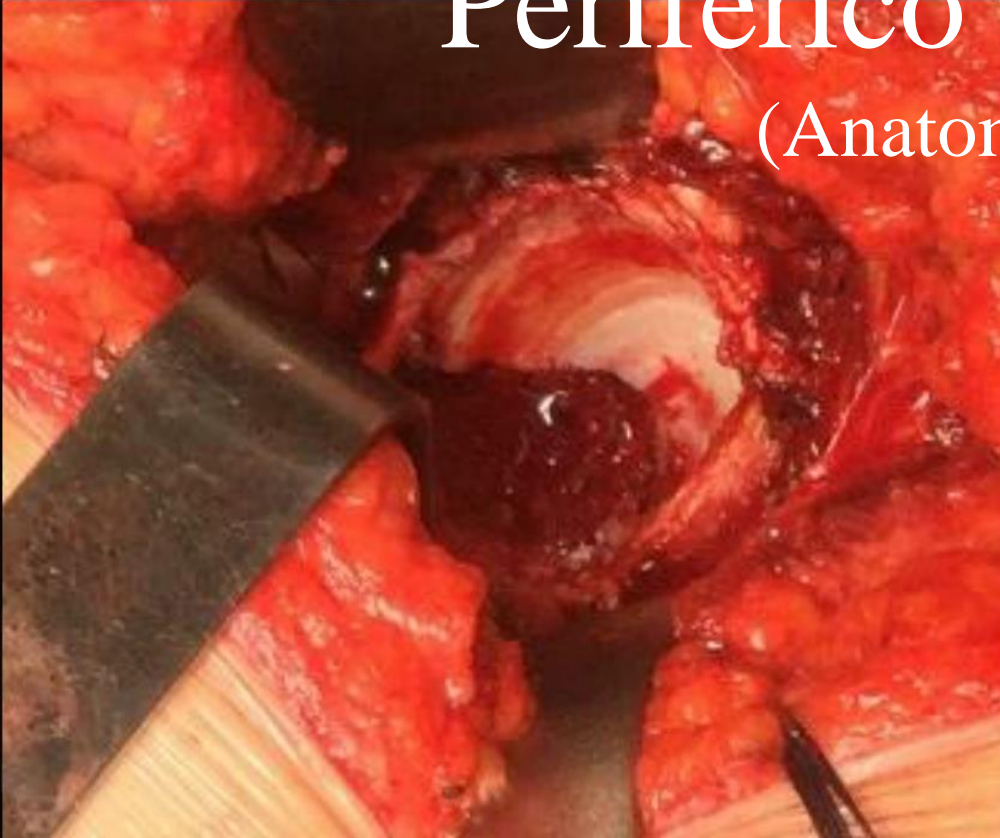This is an intraoperative photograph showing a surgical dissection. The image is oriented with anatomical labels: 'Anteriore' (Anterior) at the top, 'Posteriore' (Posterior) at the bottom, and 'Inferiore (Destro o Sinistro)' (Inferior (Right or Left)) on the right. The surgical field reveals deep tissue layers, including muscle and bone. A metal retractor system is used to hold back muscle and soft tissue, providing a clear view of the central surgical site. A pair of surgical forceps is visible in the lower-left corner, and a metal surgical instrument is in the lower-right corner. The tissue is highly vascularized and appears moist.

Inferiore
(Destro o Sinistro)

Posteriore

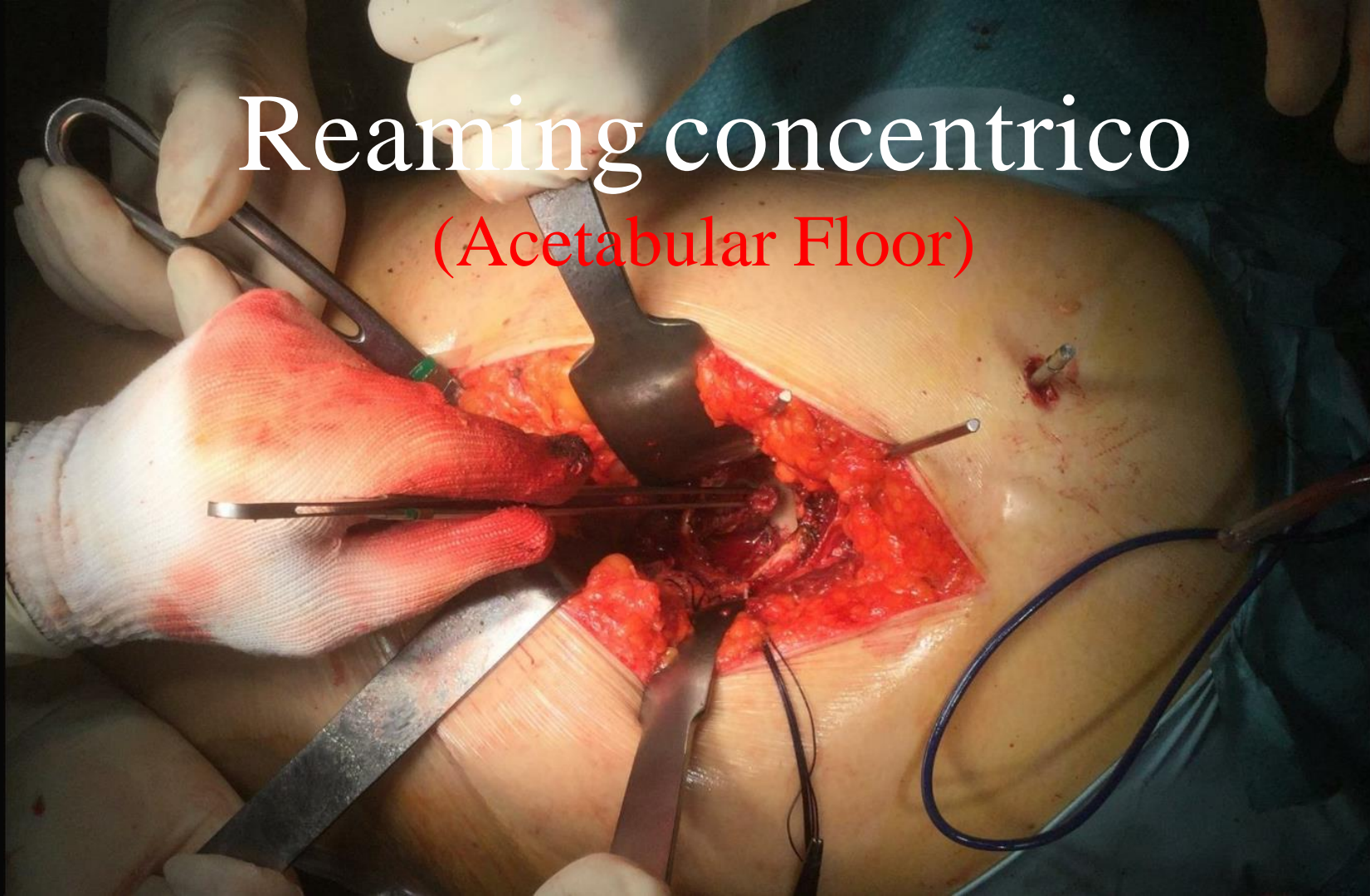
Reaming Periferico

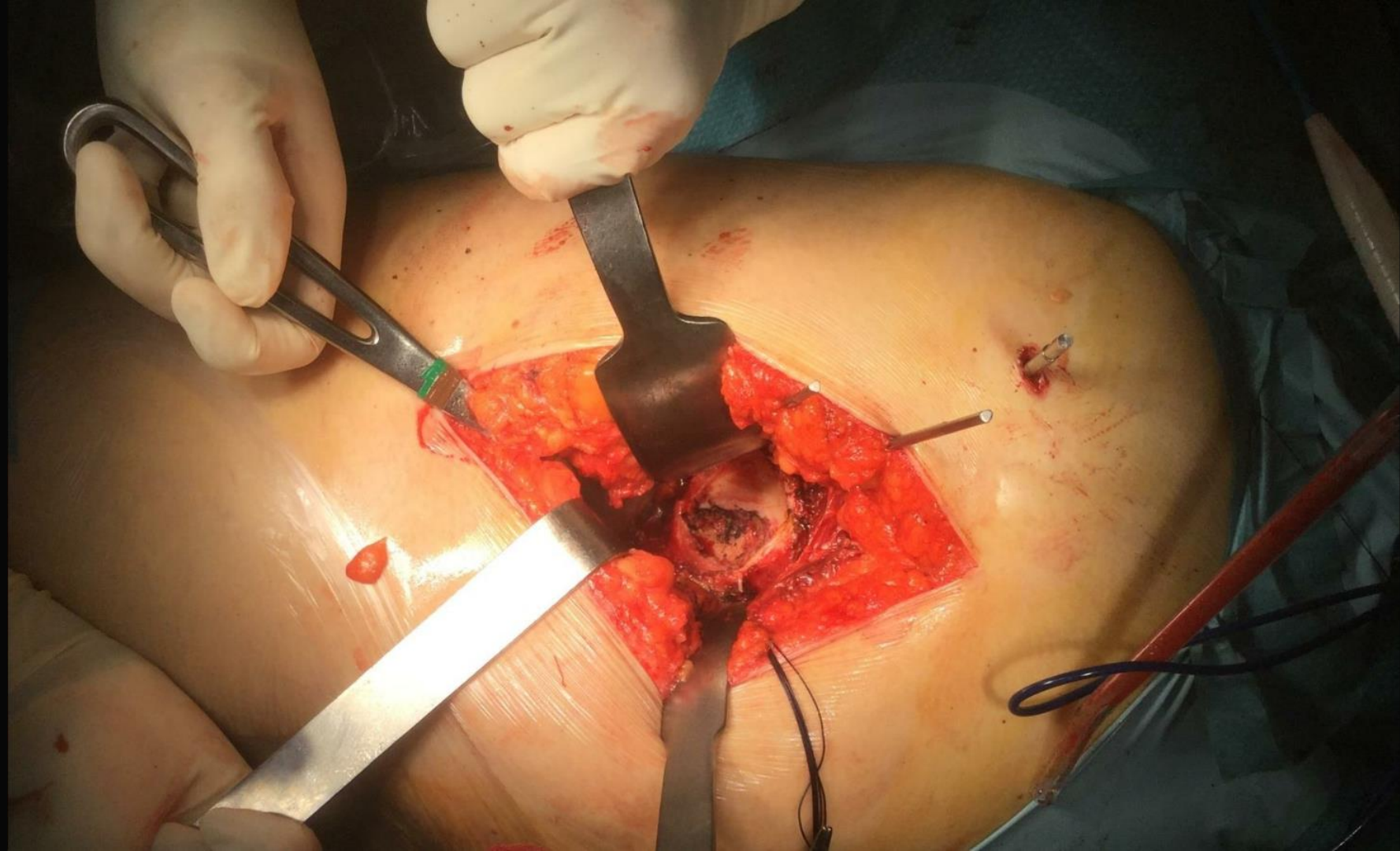(Anatomico)

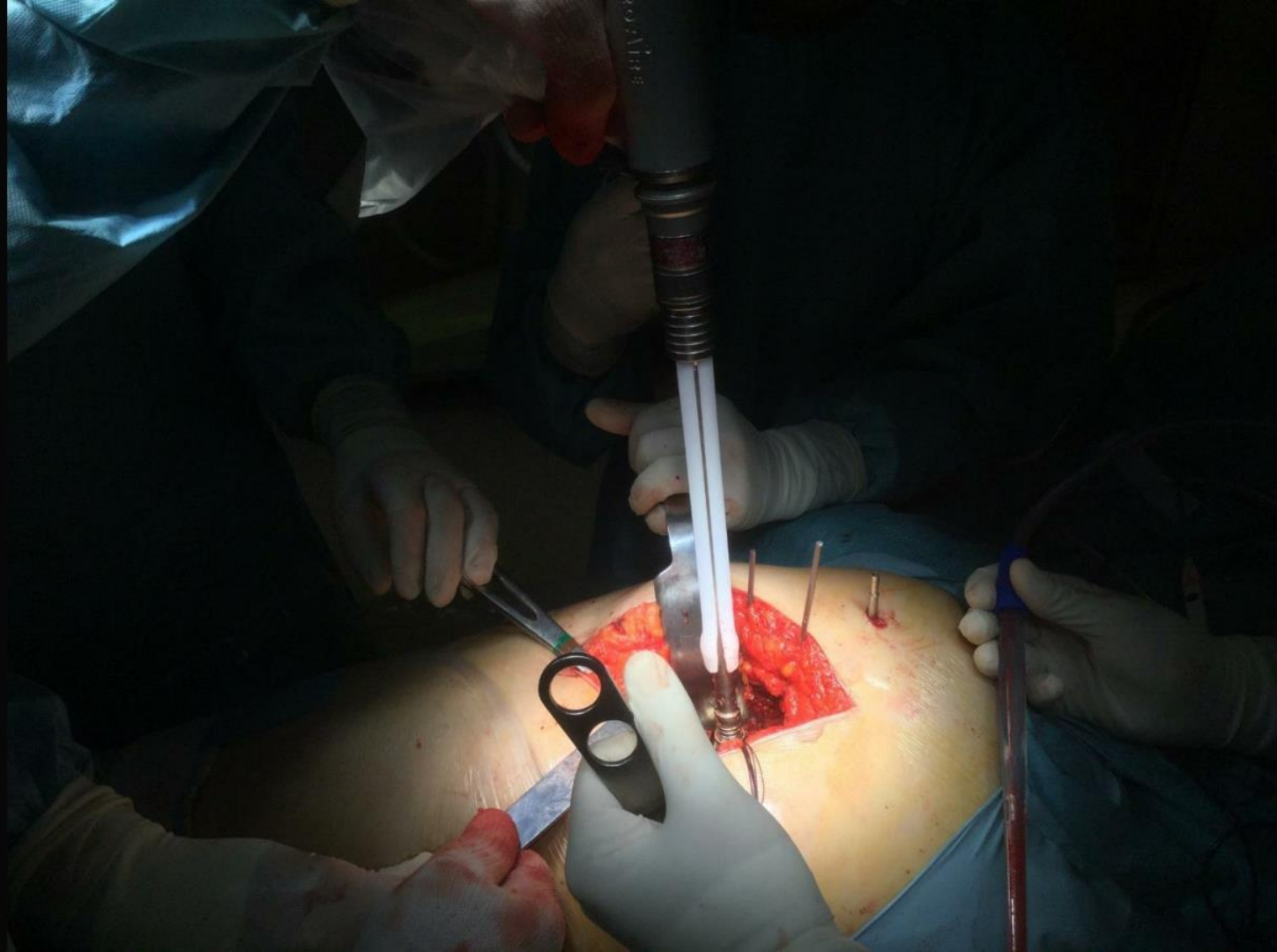


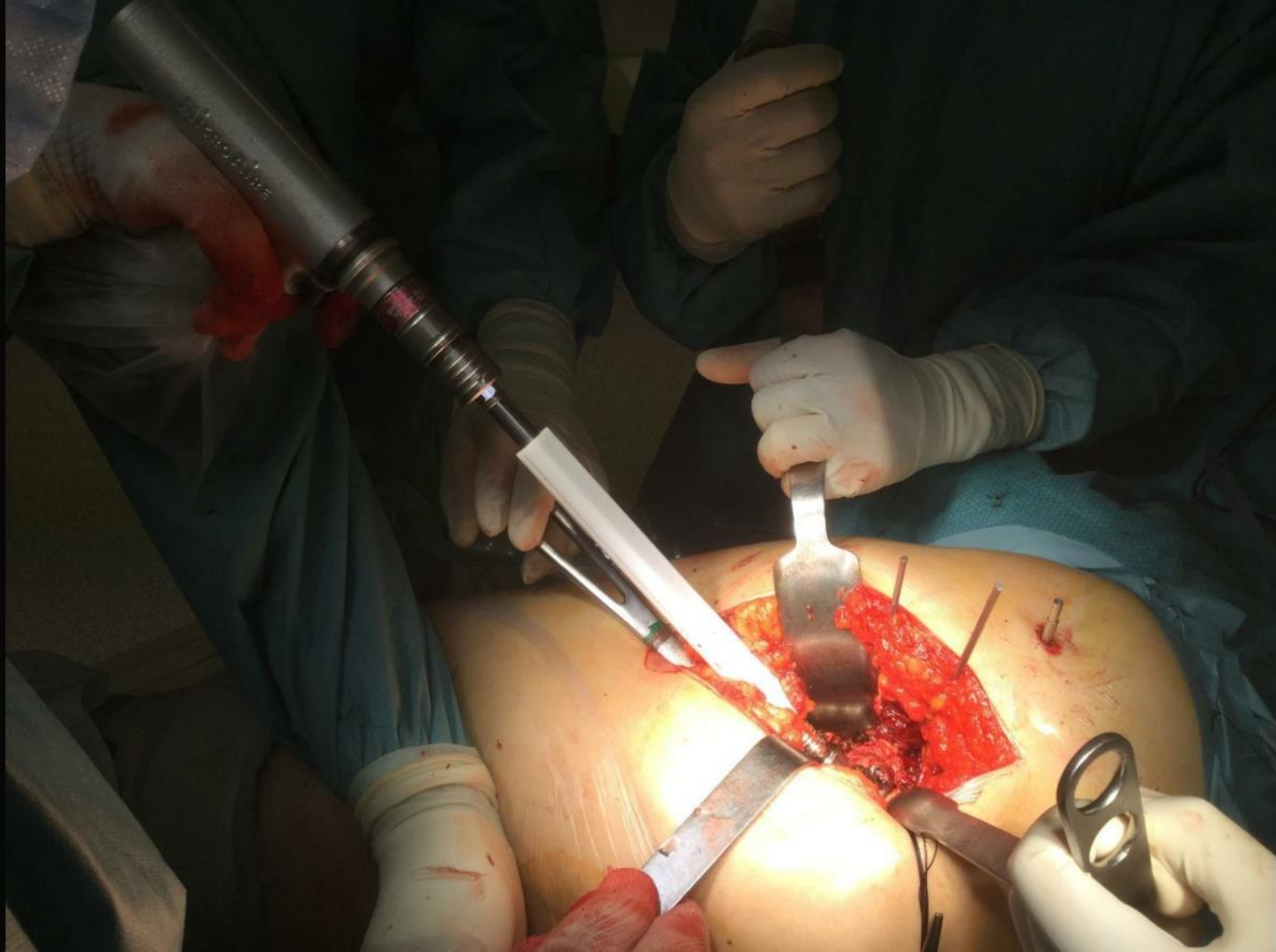Reaming concentrico

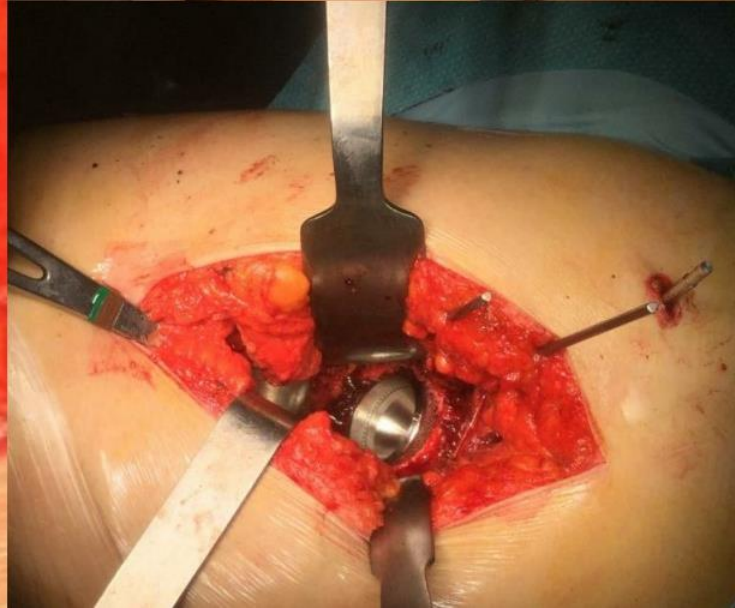
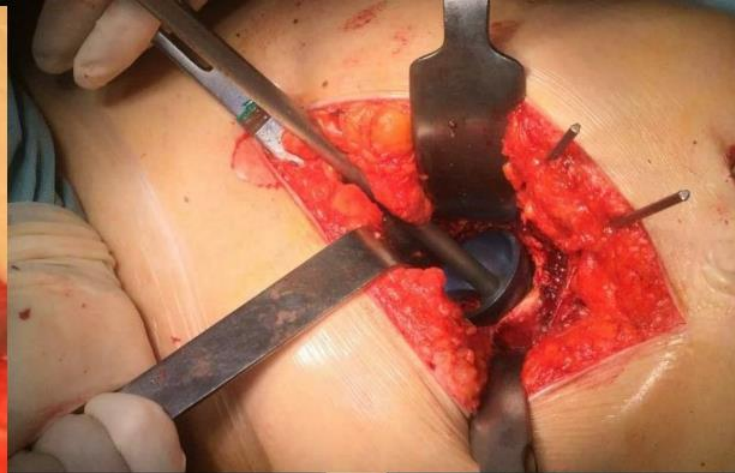
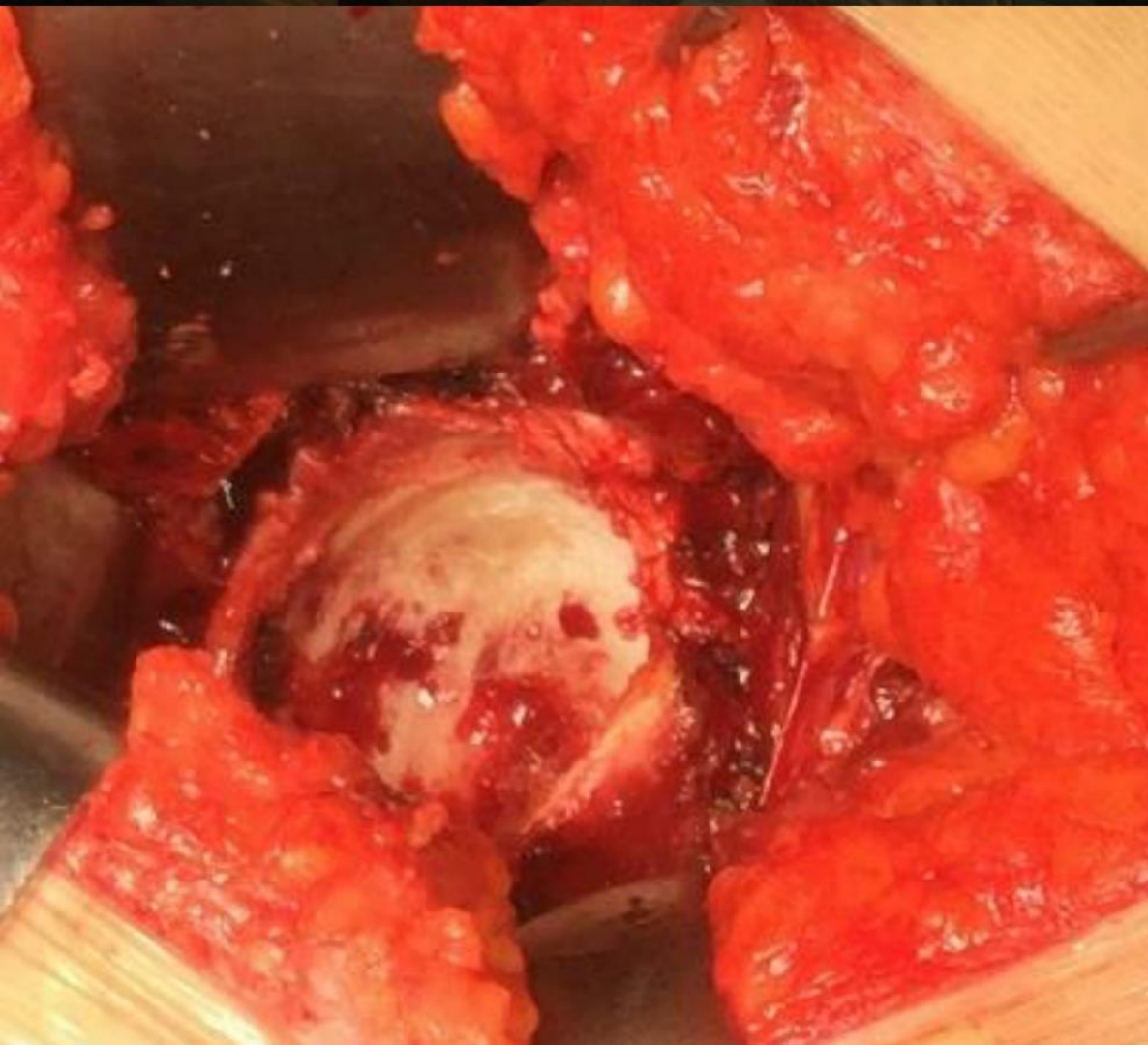(Acetabular Floor)











Cosa Dice La Letteratura.....

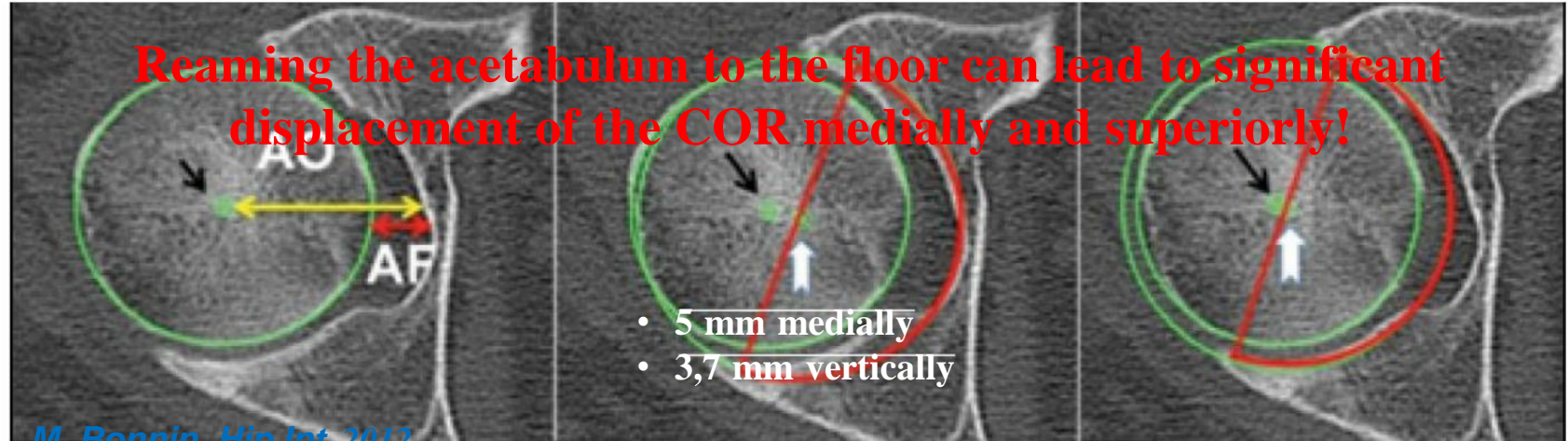


■ HIP

Restoration of the centre of rotation in primary total hip arthroplasty

THE INFLUENCE OF ACETABULAR FLOOR DEPTH AND REAMING TECHNIQUE

G. Meermans, Bone Joint J 2016





Contents lists available at ScienceDirect

The Journal of Arthroplasty

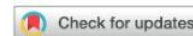journal homepage: www.arthroplastyjournal.org



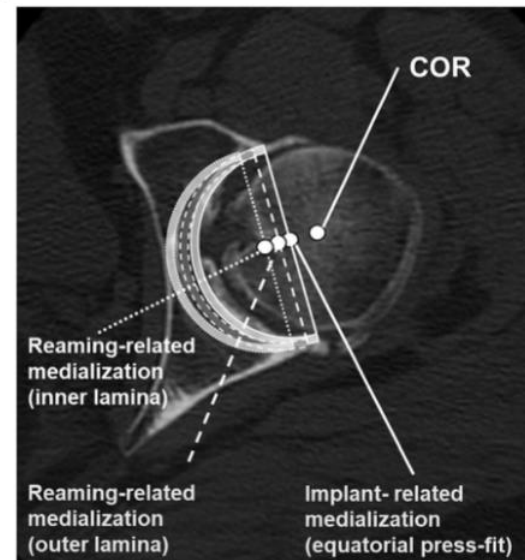
Basic Science

High Variability of Acetabular Offset in Primary Hip Osteoarthritis Influences Acetabular Reaming—A Computed Tomography—Based Anatomic Study

Christian Merle, MD, MSc ^{a,*}, Moritz M. Innmann, MD ^a, Wenzel Waldstein, MD ^b,

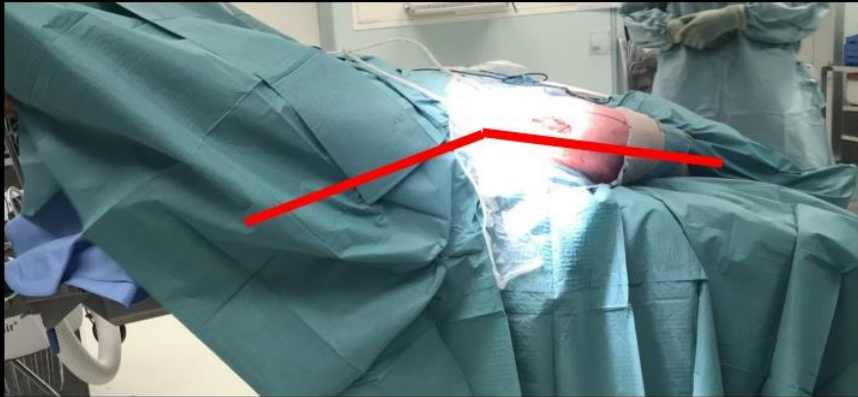


Depending on the preferred reaming technique a substantial number of patients appear at **RISK FOR EXCESSIVE CUP MEDIALIZATION!**

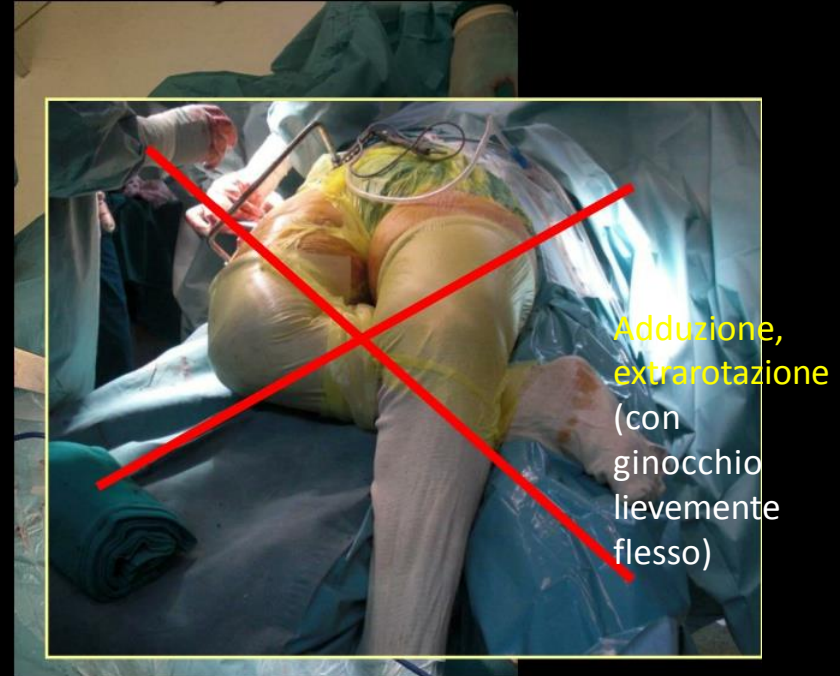


Esposizione femore prossimale: risparmio
trocanterico e abduttori, accesso e
preparazione del canale midollare

Esposizione femore prossimale: risparmio trocanterico e abduttori, accesso e preparazione del canale midollare



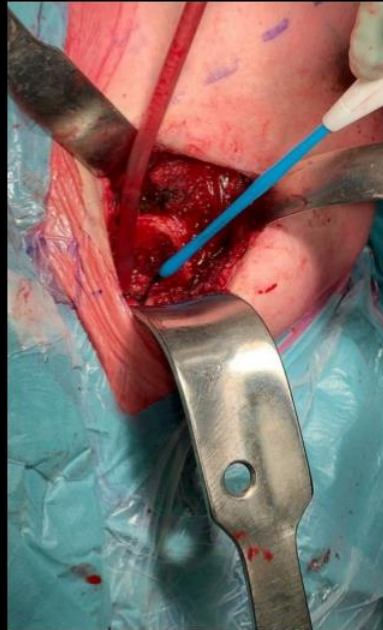Arto iperesteso



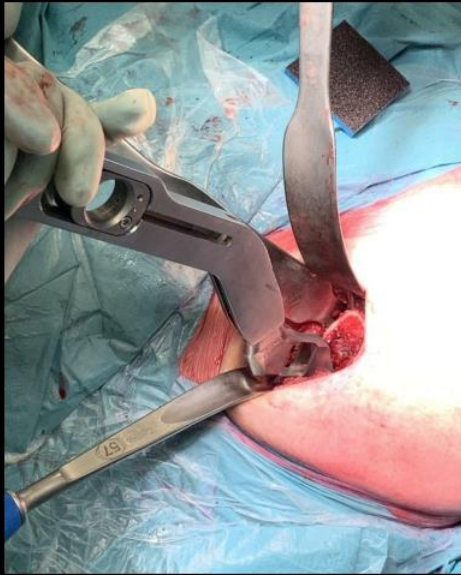
Esposizione femore prossimale: risparmio trocanterico e abducttori, accesso e preparazione del canale midollare

PEARLS AND PITFALLS

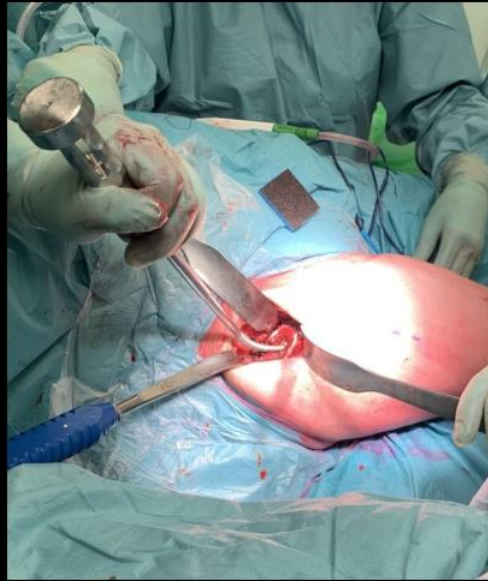Liberazione dalla capsula laterale per esporre al meglio il canale, senza arrecare danno al trocantere ed ai tessuti molli



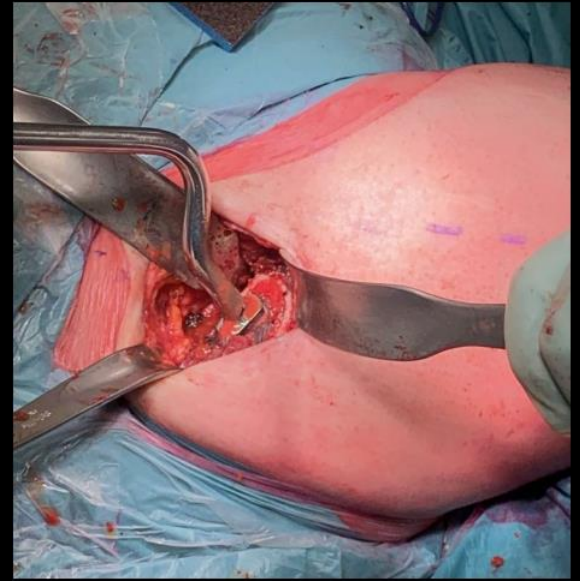
Esposizione femore prossimale: risparmio trocanterico e abducttori, accesso e preparazione del canale midollare



Box Osteotome/iniziatore:



Coda di topo

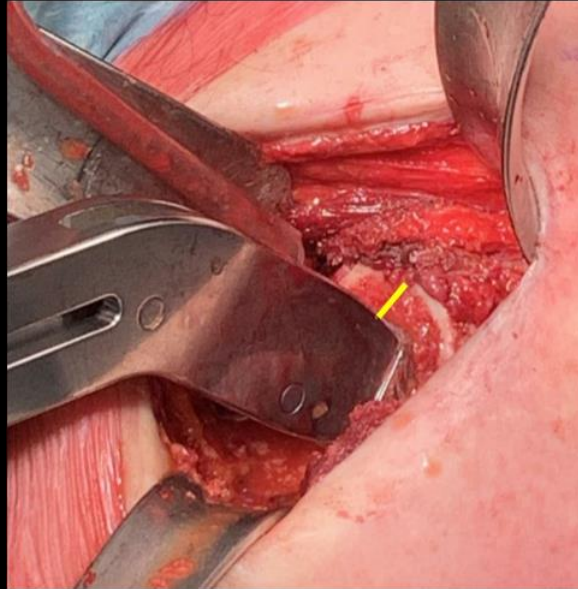


Raspe iniziale

Esposizione femore prossimale: risparmio trocanterico e abduttori, accesso e preparazione del canale midollare

PEARLS AND PITFALLS

Evitare contatto diretto anteriore della broccia per decidere giusta taglia ed evitare fratture



Esposizione femore prossimale: risparmio trocanterico e abduttori, accesso e preparazione del canale midollare

[Clin Orthop Relat Res.](#) 2005 Dec;441:115-24.

Single-incision anterior approach for total hip arthroplasty on an orthopaedic table.

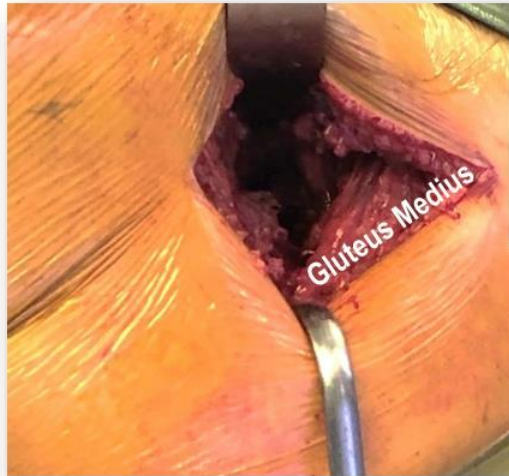
[Matta JM](#)¹, [Shahrdar C](#), [Ferguson T](#).



Author information

1 Department of Orthopaedic Surgery, Good Samaritan Hospital, University of Southern California, Los Angeles, CA 90017, USA.
info@hipandpelvis.com

as factors influencing total hip arthroplasty stability. We describe a total hip arthroplasty technique done through a single, tissue sparing anterior approach that allows implantation of the femoral and acetabular components **without detaching or sectioning any of the muscles and tendons around the hip joint.** A series of 437 consecutive, unselected patients who had 494 primary total hip arthroplasty surgeries done

Via Antero-laterale: Esposizione del femore



 **The Anterolateral Approach:
The “Other” Anterior Approach To The Hip** 

R. Civinini, C. Carulli, F. Matassi, M. Villano, M. Innocenti.
Orthopedic Department of the University of Florence - A.O.U. Careggi, C.T.O. Firenze, Italy

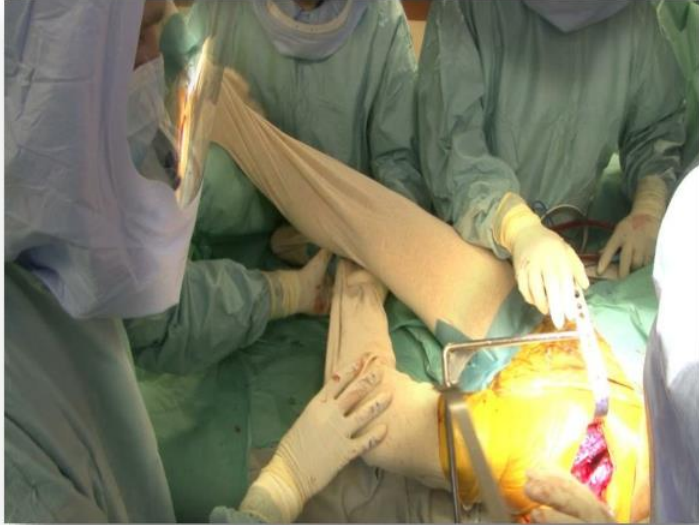SE 08

AAOS
AMERICAN ACADEMY OF
ORTHOPAEDIC SURGEONS

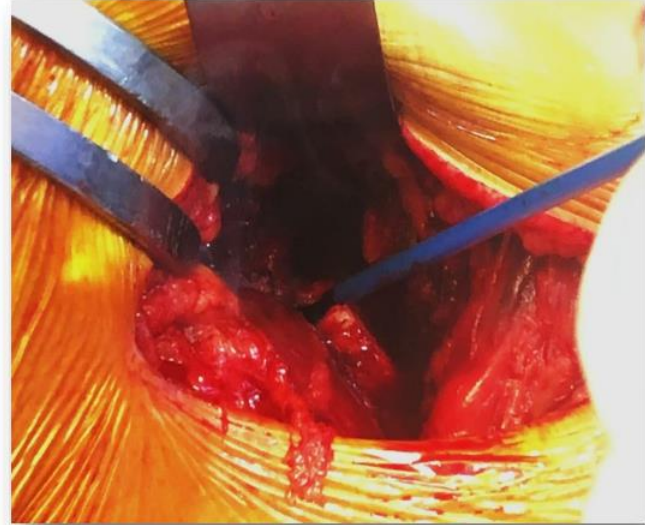
2016 Annual Meeting
Orange County Convention Center, West Building - Orlando, FL
Meeting Dates: March 1-4

La via antero-laterale  prevede il completo risparmio del medio gluteo

Via Antero-laterale: Esposizione del femore

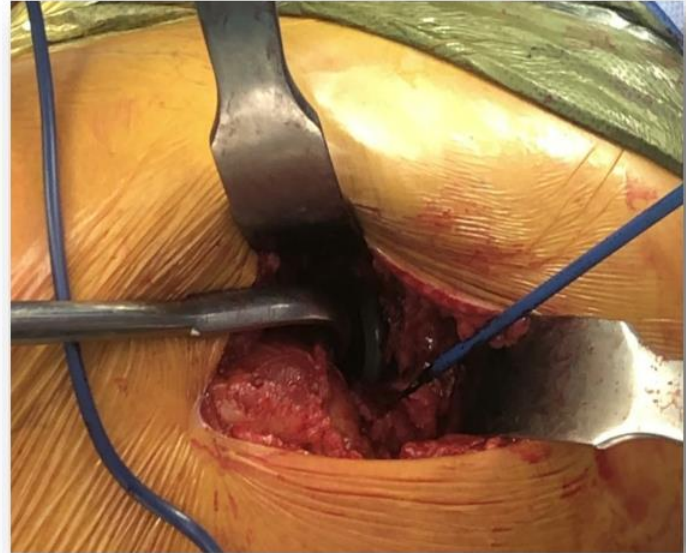
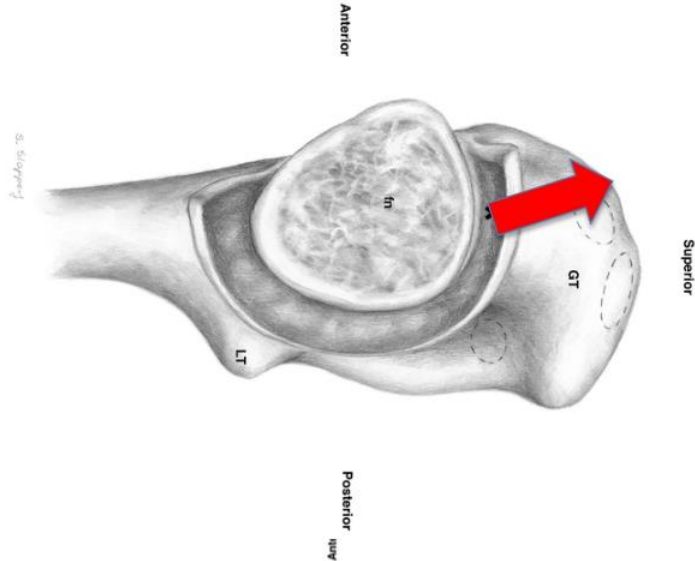


L'arto viene posizionato in
40° adduzione e 90° extrarotazione
(no iperestensione)



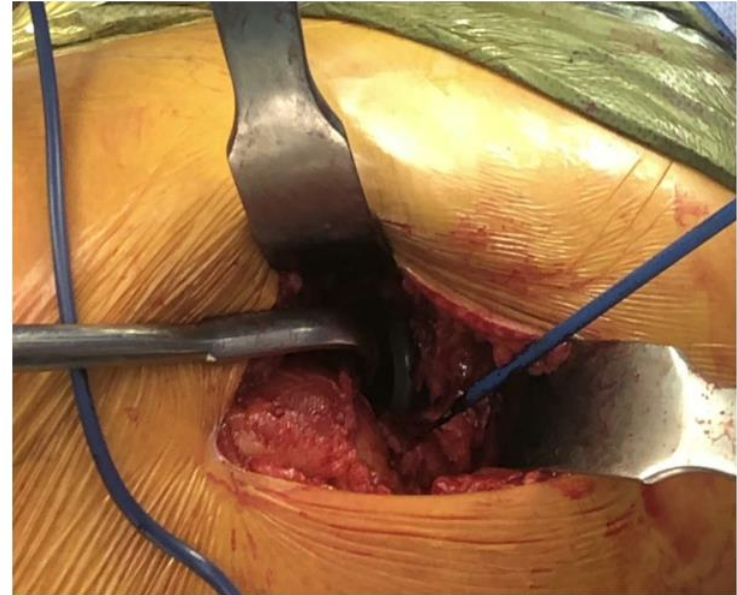
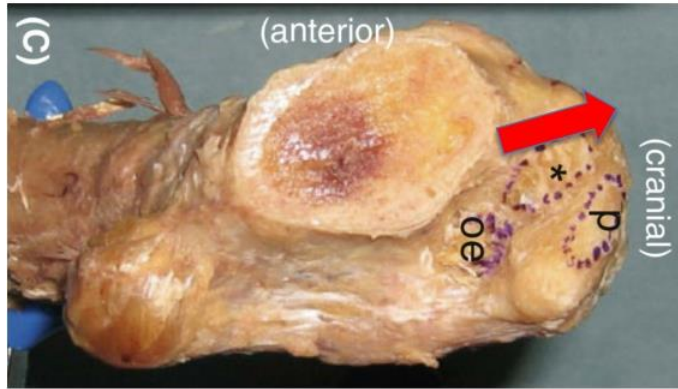
Eseguiamo per primo il release
della capsula inferiore
(Ligamento pubo-femorale)

Via Antero-laterale: Esposizione del femore



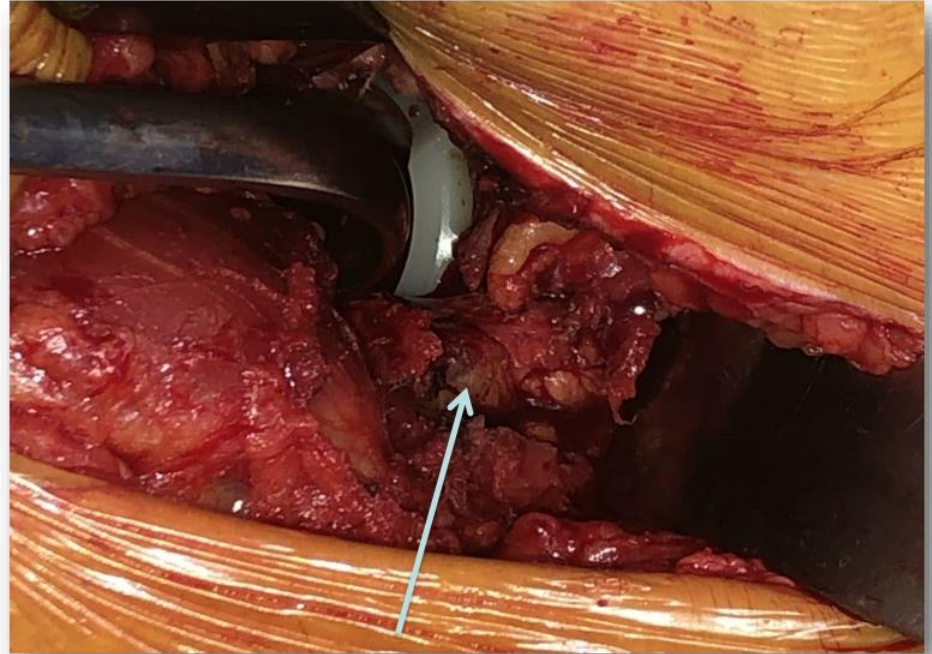
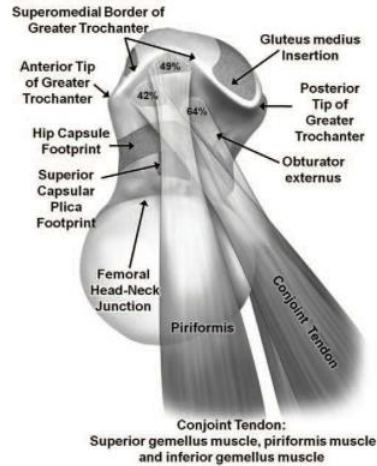
Release della capsula superiore
fino alla corticale posteriore

Via Antero-laterale: Esposizione del femore



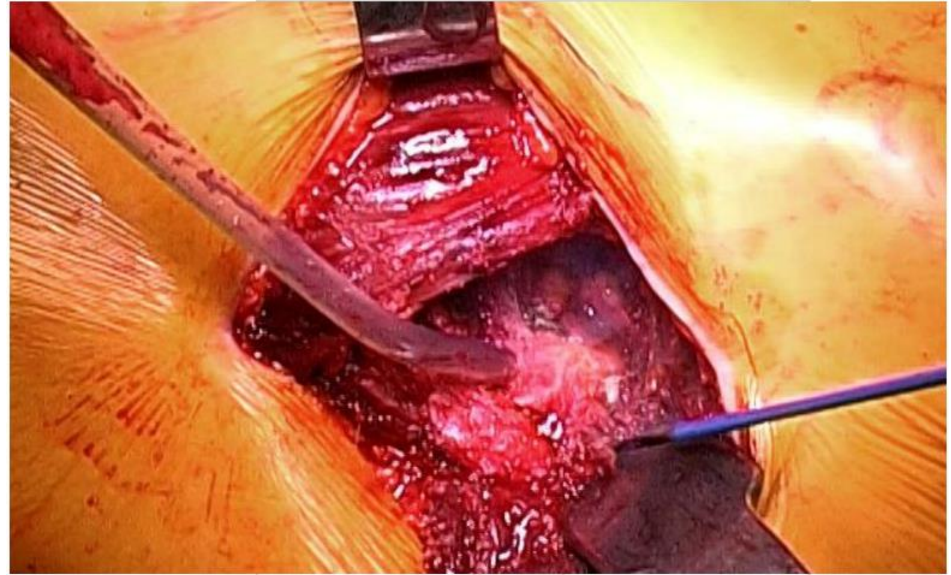
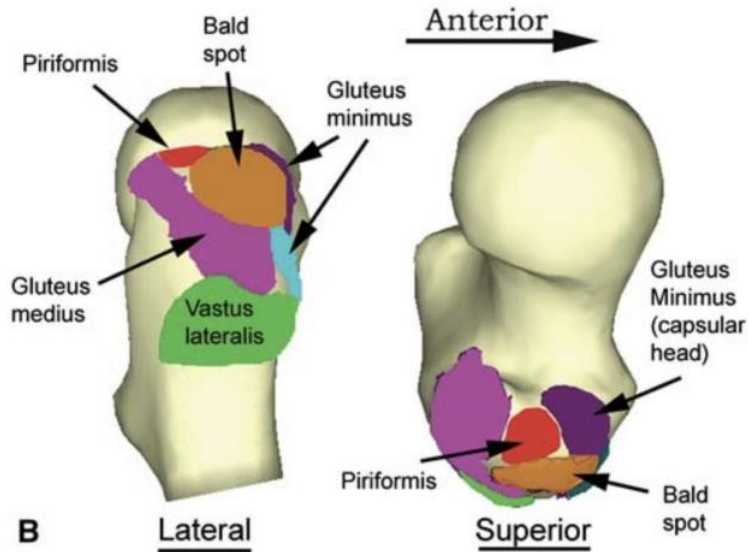
Si tratta della zona di inserzione del
tendine congiunto (*) e del piriforme

Via Antero-laterale: Esposizione del femore



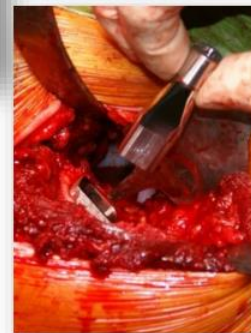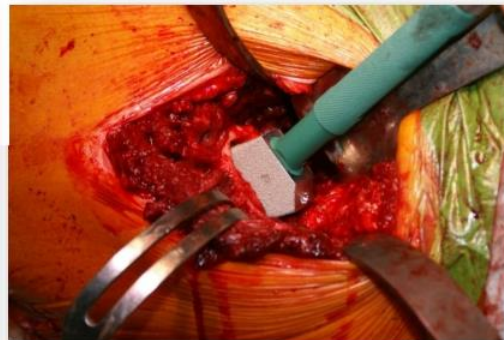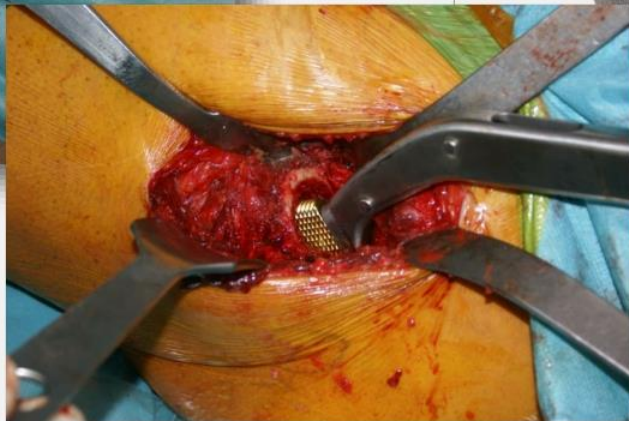
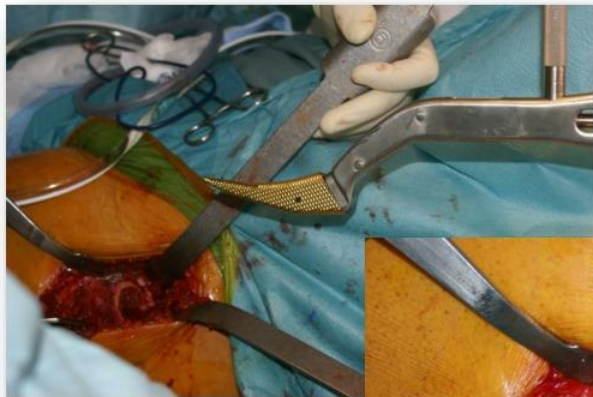Si scopre il fat pad
Si scopre il fat pad

Via Antero-laterale: Esposizione del femore



Al di sotto del grasso si trova il «Bald Spot» quella zona di trocantere fra medio e piccolo gluteo dove non vi sono inserzioni muscolari

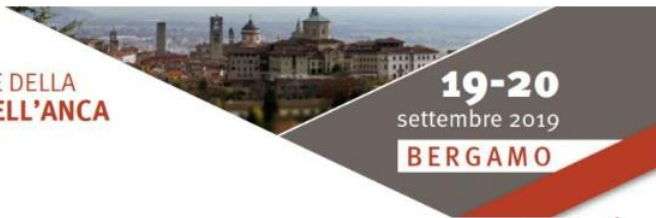Via Antero-laterale: Esposizione del femore



Utilizziamo steli a risparmio
osseo trocanterico



CONGRESSO NAZIONALE DELLA
SOCIETÀ ITALIANA DELL'ANCA

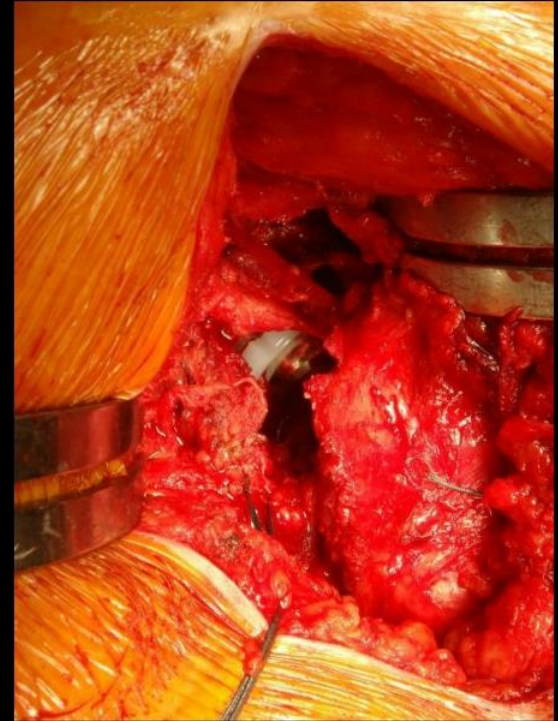
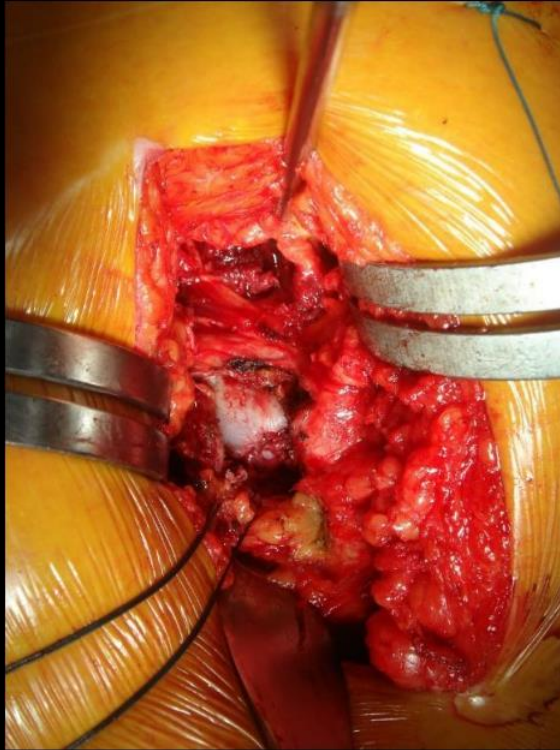
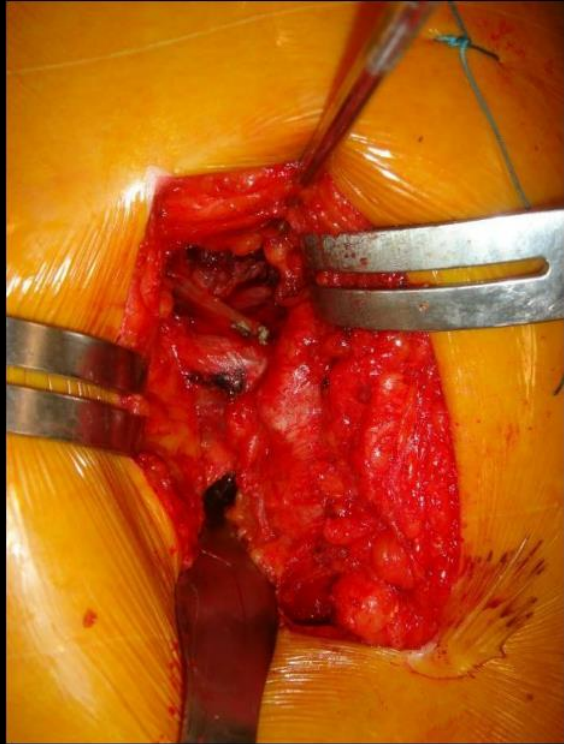


LA VIA POSTERO LATERALE

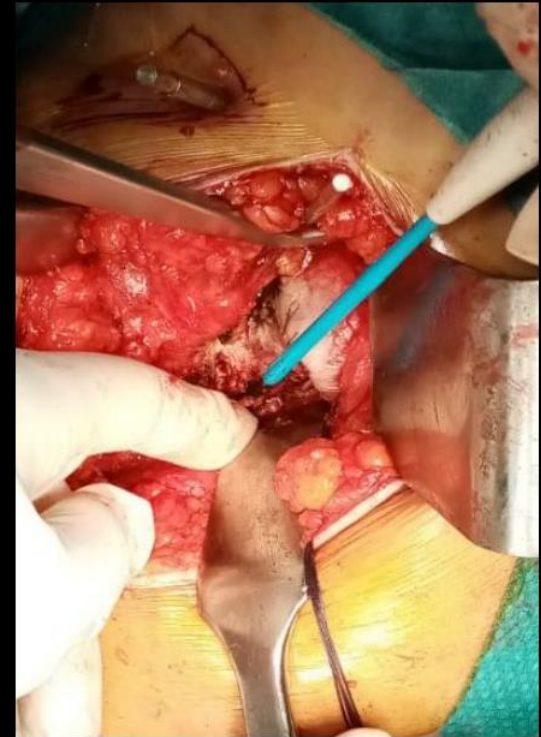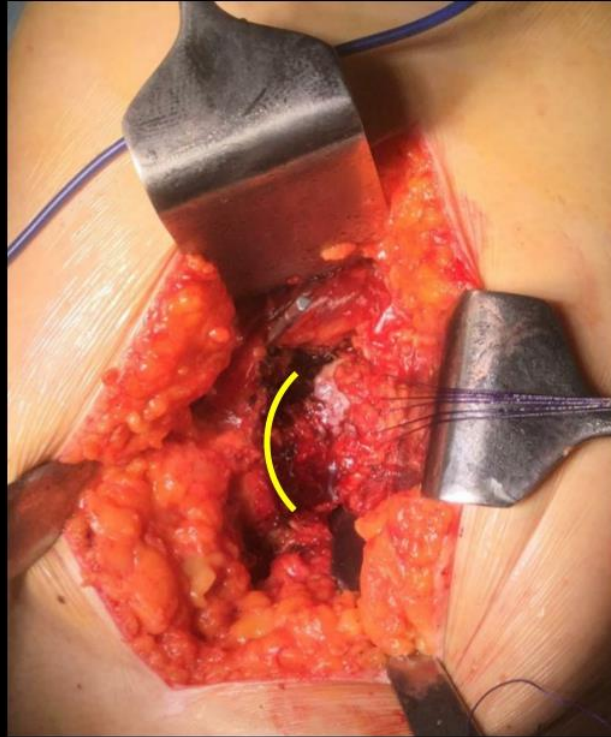
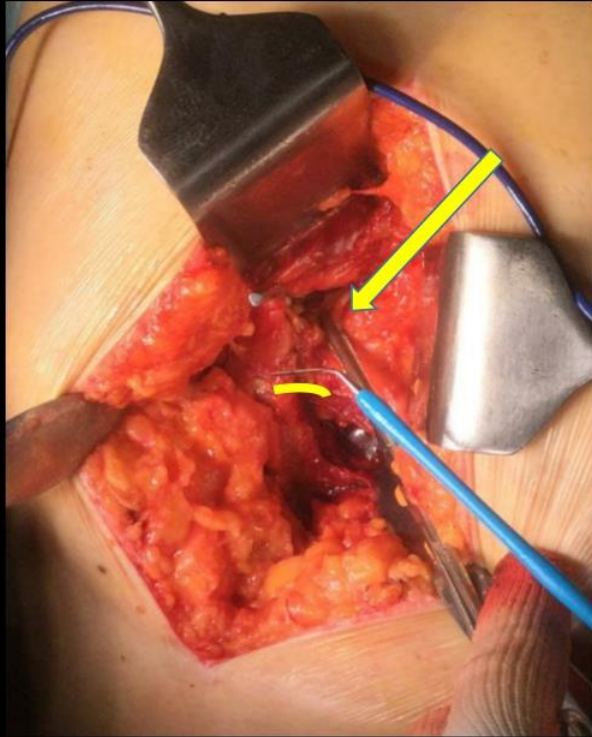
ESPOSIZIONE FEMORE PROSSIMALE:

Risparmio trocanterico e Abduttori,
Accesso e preparazione canale midollare

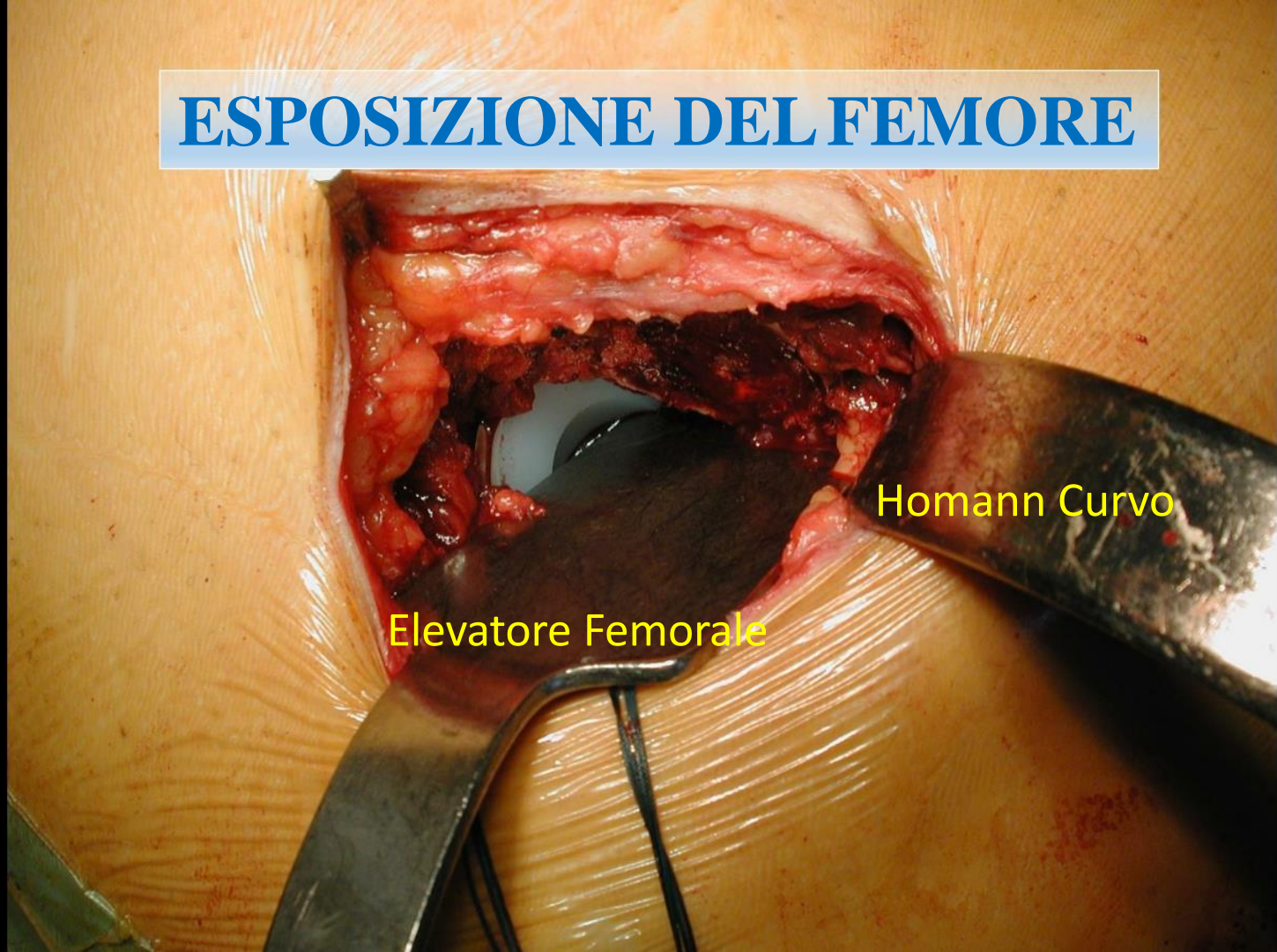
ABDUTTORI: Conservazione del Piriforme



ABDUTTORI: Resezione e isolamento



ESPOSIZIONE DEL FEMORE



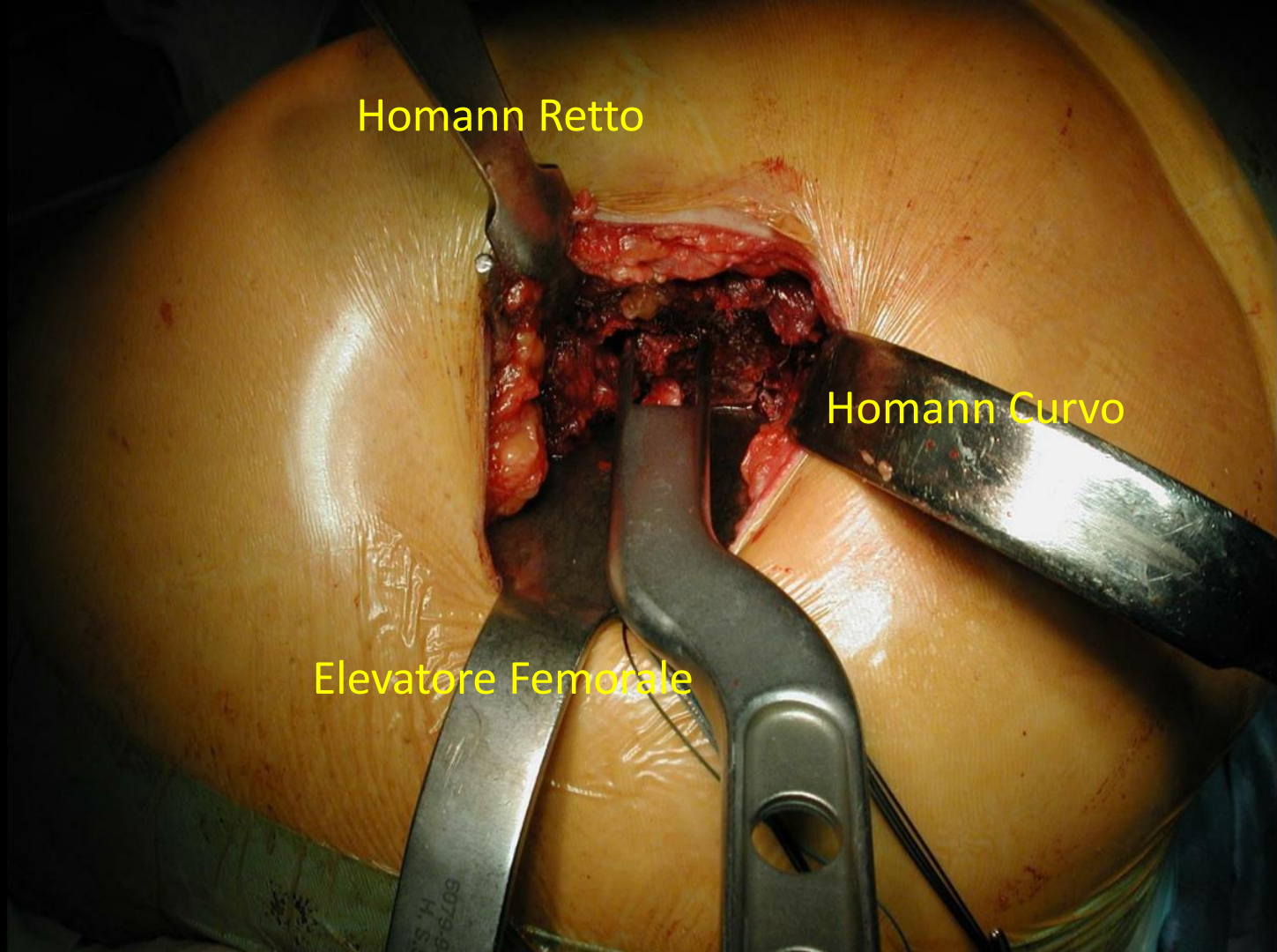
Homann Curvo

Elevatore Femorale

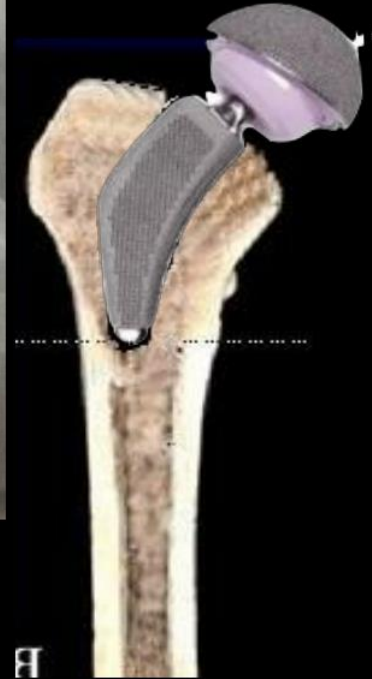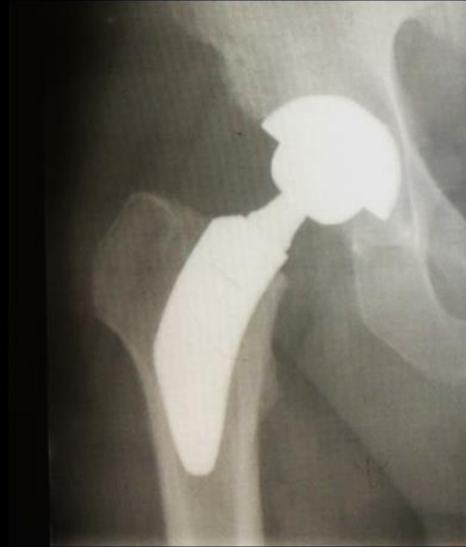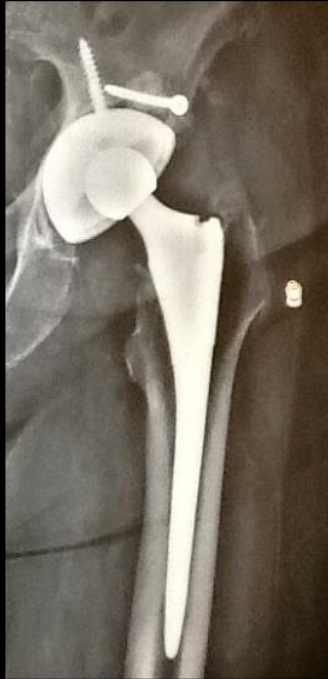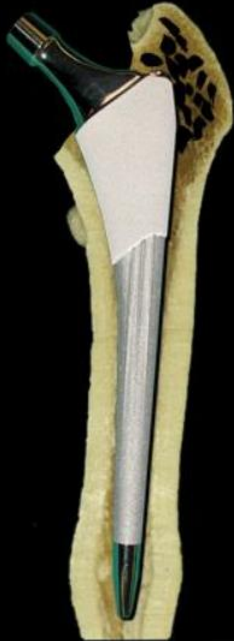Homann Retto

Homann Curvo

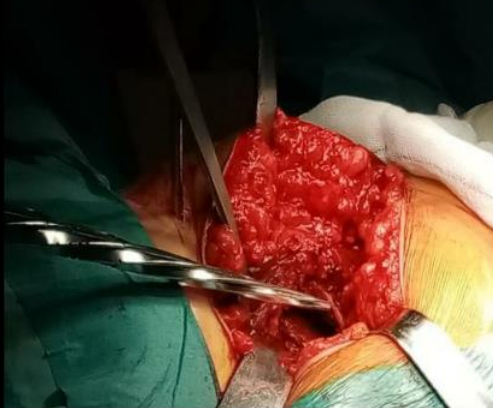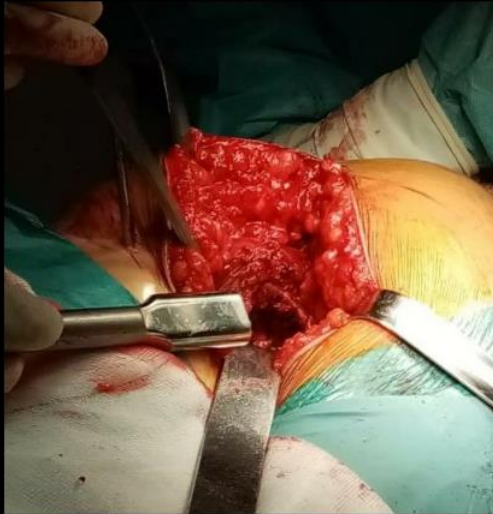Elevatore Femorale



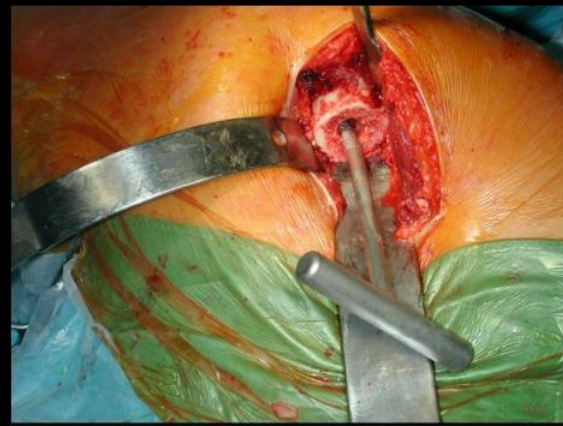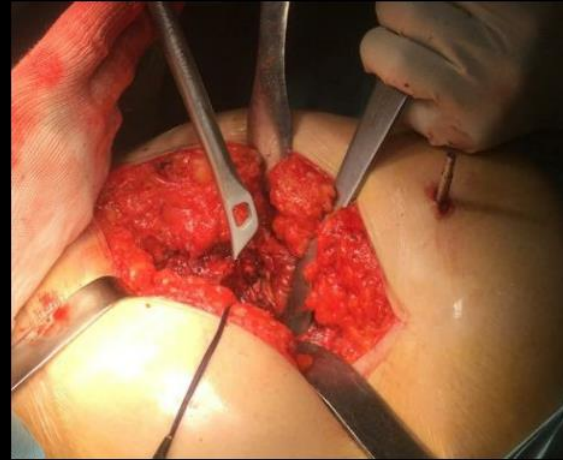
RISPARMIO DEL GRAN TROCANTERE E PREPARAZIONE DEL CANALE:



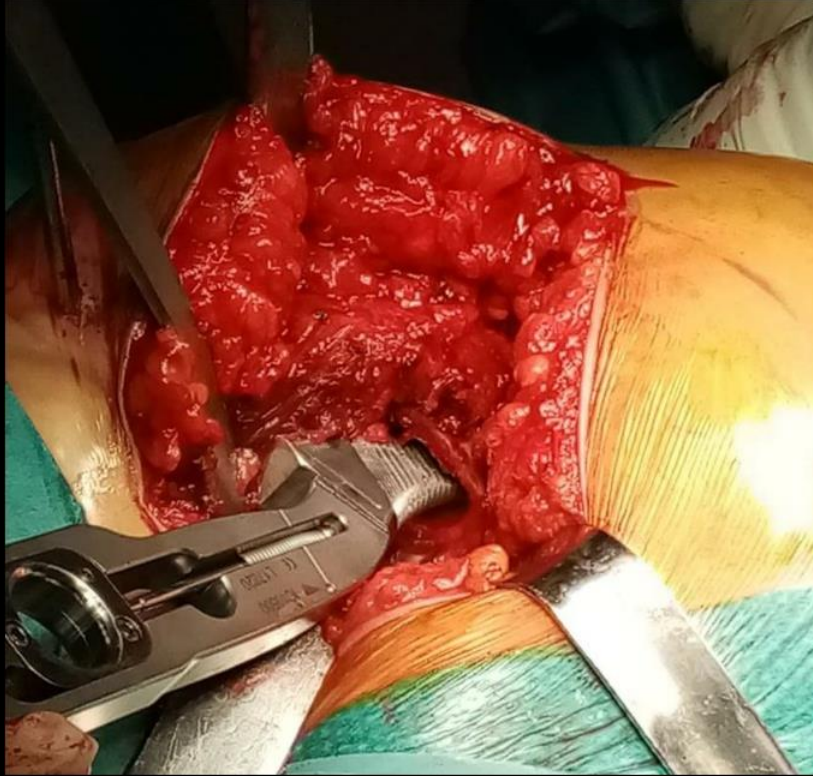
STELO STANDARD



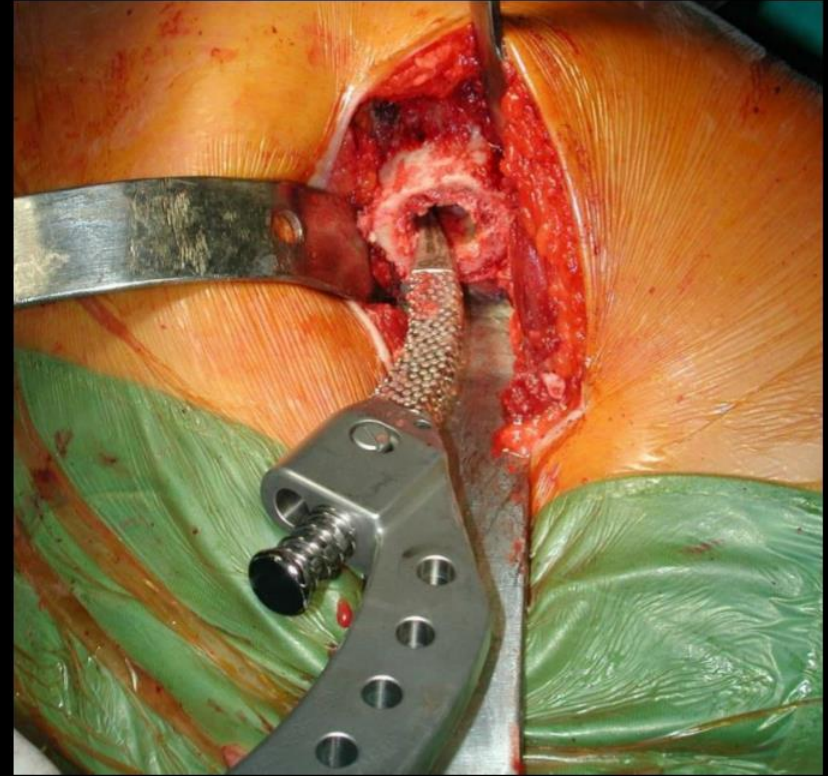
CONSERVAZIONE DI COLLO



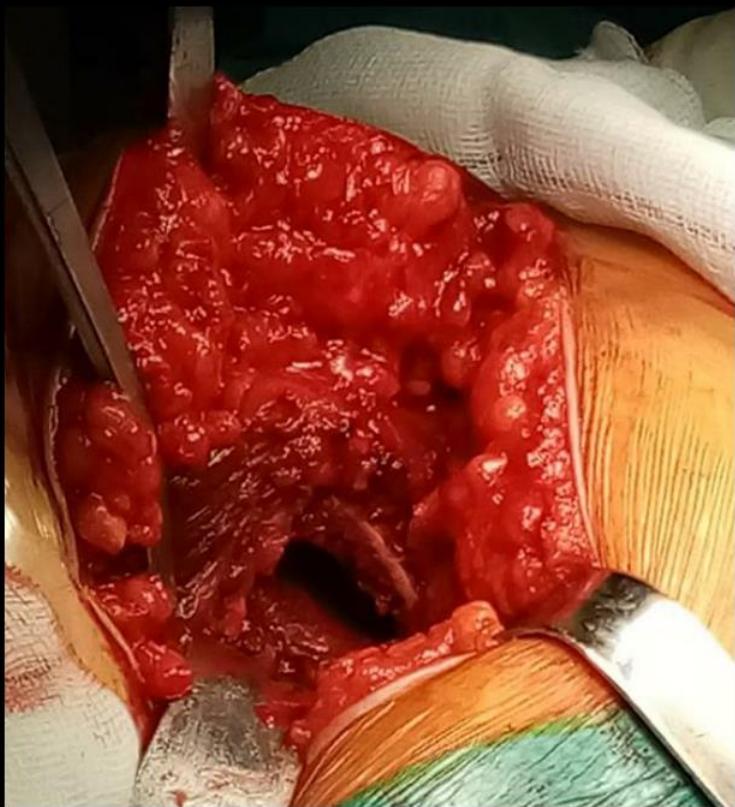STELO STANDARD



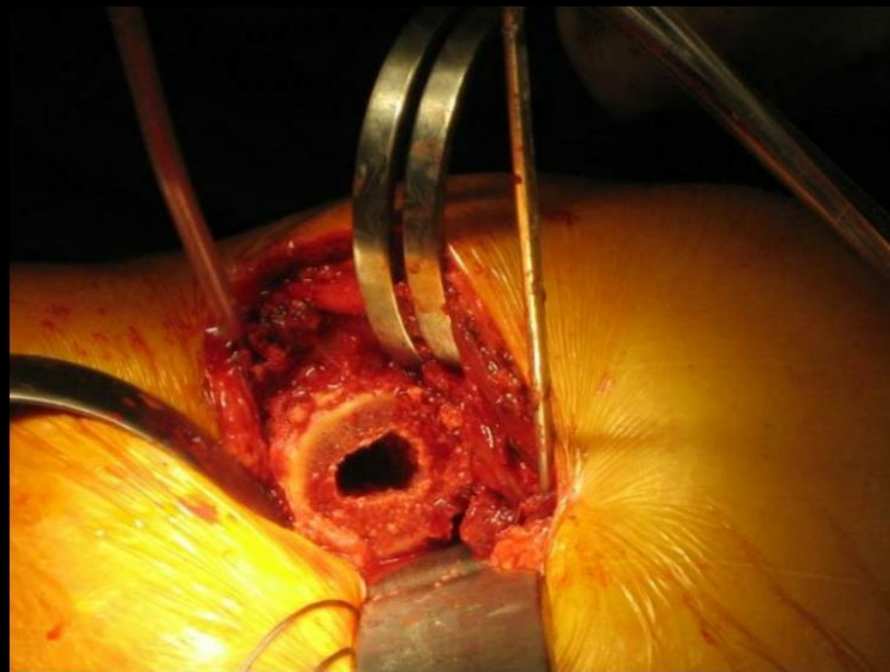
CONSERVAZIONE DI COLLO



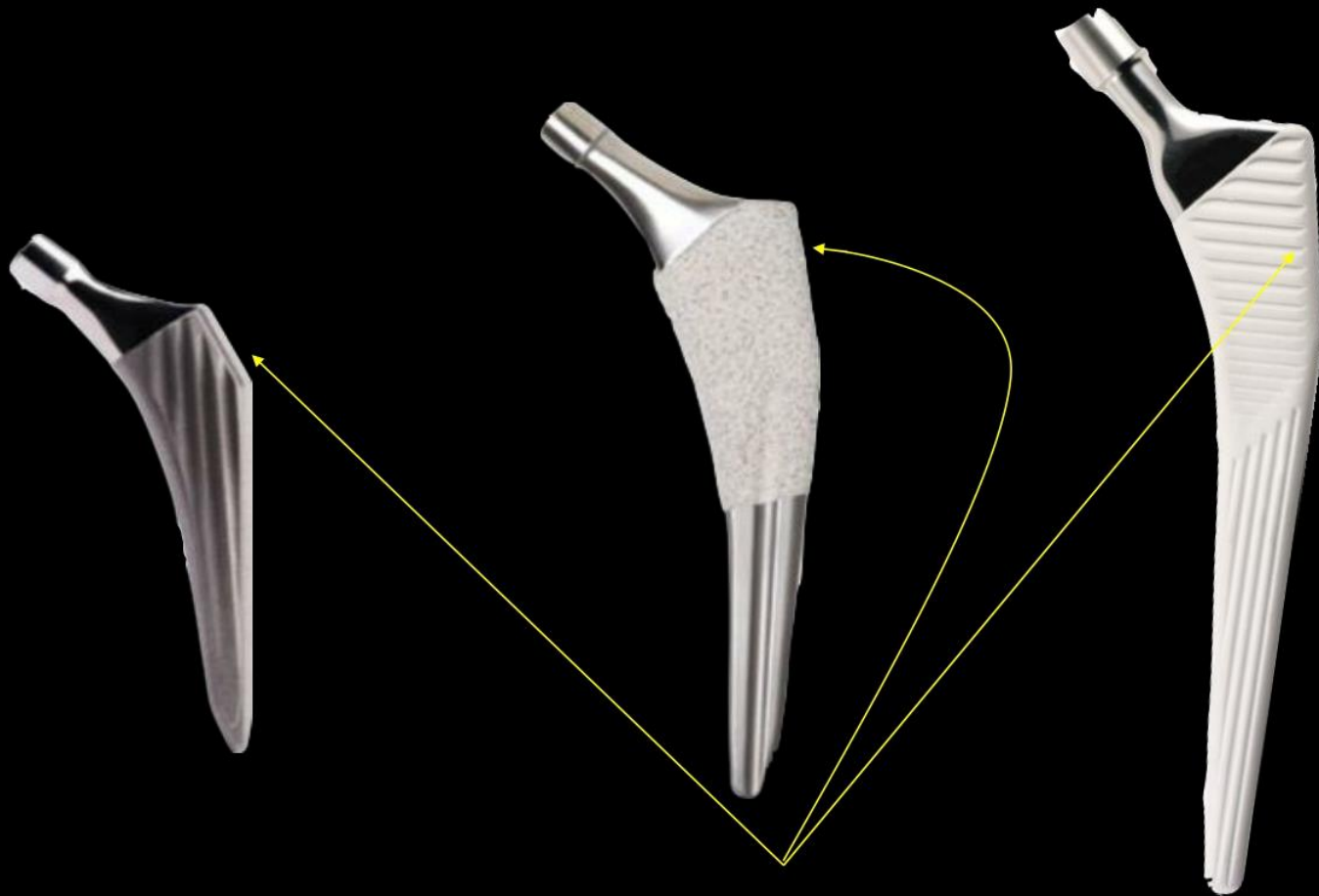
STELO STANDARD



CONSERVAZIONE DI COLLO

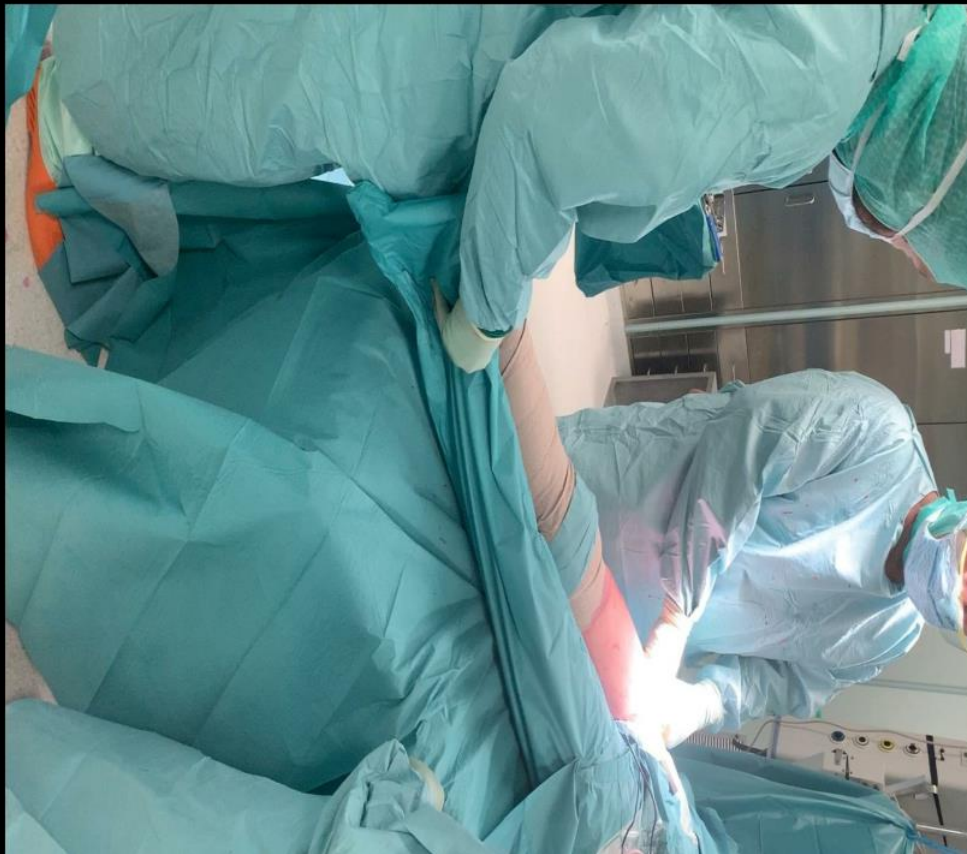

STELI TRADIZIONALI A RISPARMIO DEL TROCANTERE E DEL CANALE



Verifica intraoperatoria di offset e dismetria

Verifica intraoperatoria di offset e dismetria



Verifica intraoperatoria di offset e dismetria

Orthop Traumatol Surg Res. 2018 Dec;104(8):1143-1148. doi: 10.1016/j.otsr.2018.06.020. Epub 2018 Oct 10.

Leg length discrepancy after total hip arthroplasty: Can leg length be satisfactorily controlled via anterior approach without a traction table? Evaluation in 56 patients with EOS 3D.

Lecoanet P¹, Vargas M², Pallaro J³, Thelen T², Ribes C², Fabre T².

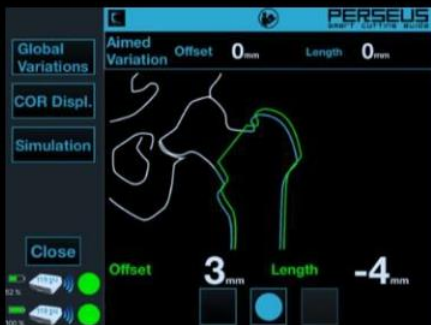Author information

- 1 Service de chirurgie orthopédique, CHU Bordeaux, place Amélie-Raba-Léon, 33000 Bordeaux, France. Electronic address: paul.lecoanet@chu-bordeaux.fr.
- 2 Service de chirurgie orthopédique, CHU Bordeaux, place Amélie-Raba-Léon, 33000 Bordeaux, France.
- 3 Service de chirurgie orthopédique, hôpital privé Saint-Martin, allée des Tulipes, 33600 Pessac, France.

DISCUSSION: Although the frequency of LLD after THA in our study was consistent with earlier reports, our results show that good limb length control can be obtained via the DAA with a standard operating table. Thus, 7 of the 11 patients with a shorter limb and 1 of 4 with a longer limb before THA had equal limb lengths after THA, and only 8.9% of patients experienced a detrimental increase in limb length after THA. The DAA without a traction table allows satisfactory intra-operative limb length control based on visualisation of anatomical landmarks (antero-superior iliac spines and medial malleoli). This technique is therefore valuable for limiting the risk of LLD. When combined with 3D EOS planning, it may increase the accuracy of limb length adjustment.

Verifica intraoperatoria di offset e dismetria

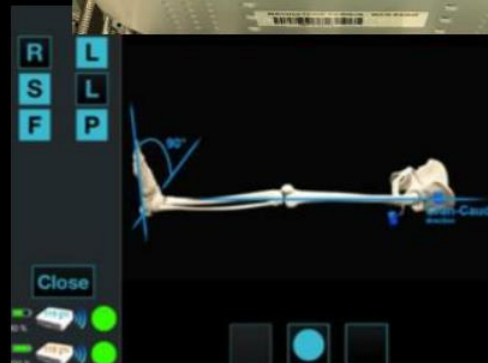
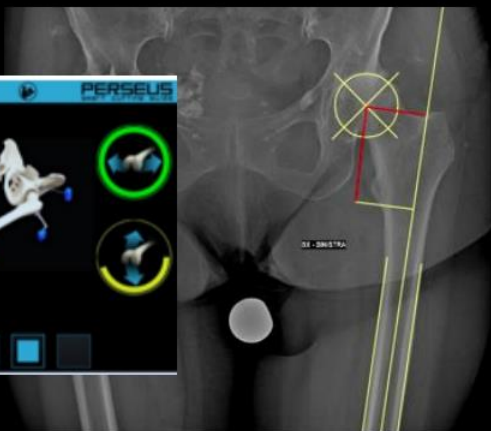
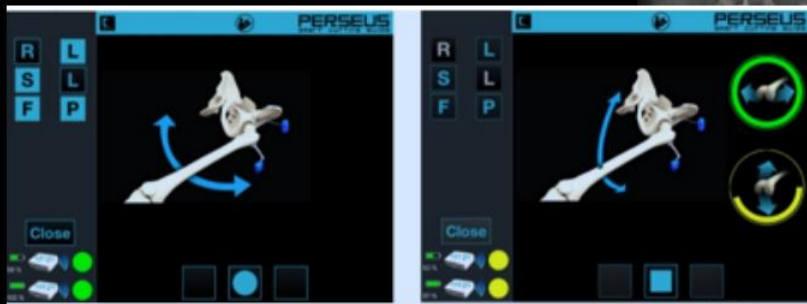LA NOSTRA ESPERIENZA...



VALUTAZIONE PRELIMINARE DI TRIAL CLINICO
RANDOMIZZATO SULL'UTILIZZO DI SENSORI INERZIALI
IN ARTROPROTESI D'ANCA PER LA GESTIONE
DELL'OFF-SET E DELLA DISMETRIA INTRAOPERATORIA

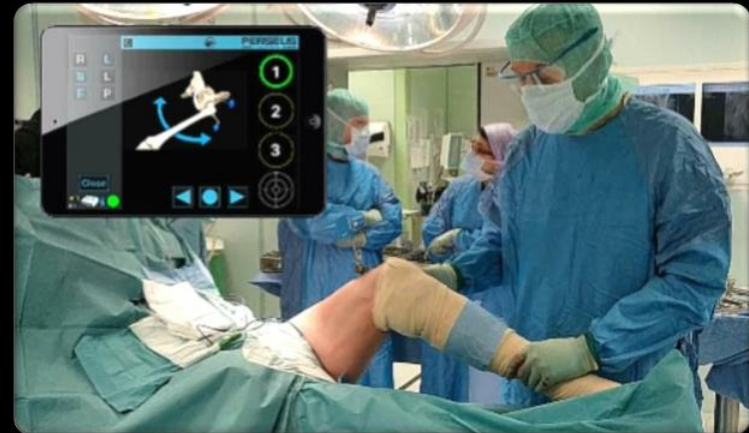


Tesi di Laurea in Ortopedia e Traumatologia

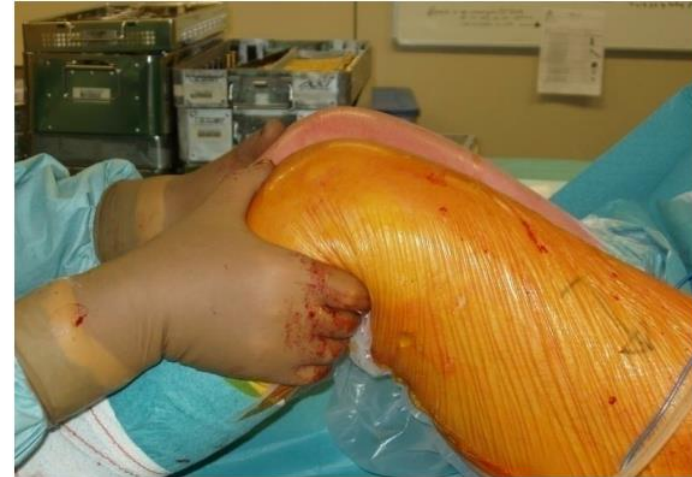
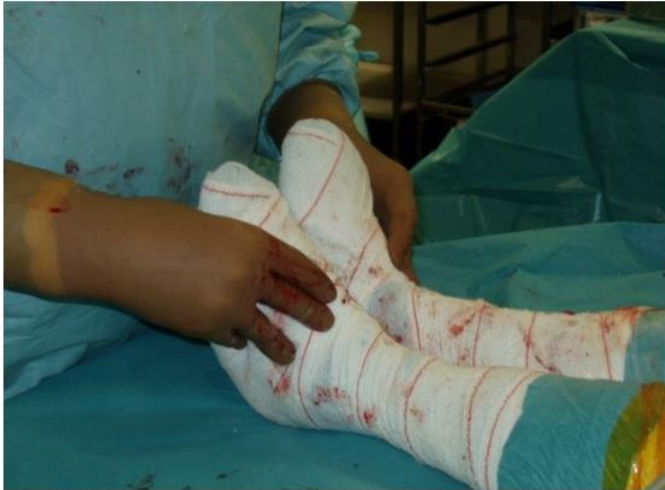
Verifica intraoperatoria di offset e dismetria

LA NOSTRA ESPERIENZA...



Via Antero-laterale: Verifica intra-operatoria di lunghezza e offset



Con la componente di prova, si esegue la riduzione ed i test di stabilità, mobilità ed il controllo della lunghezza degli arti secondo planning preoperatorio



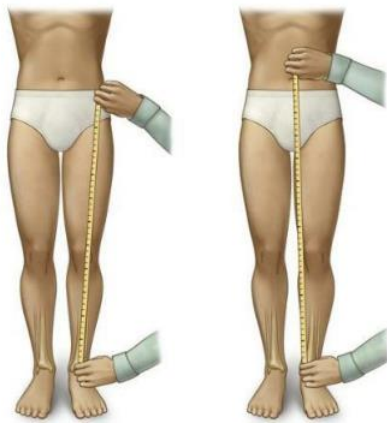
CONGRESSO NAZIONALE DELLA
SOCIETÀ ITALIANA DELL'ANCA

19-20
settembre 2019
BERGAMO

LA VIA POSTERO LATERALE

VERIFICA INTRAOPERATORIA:

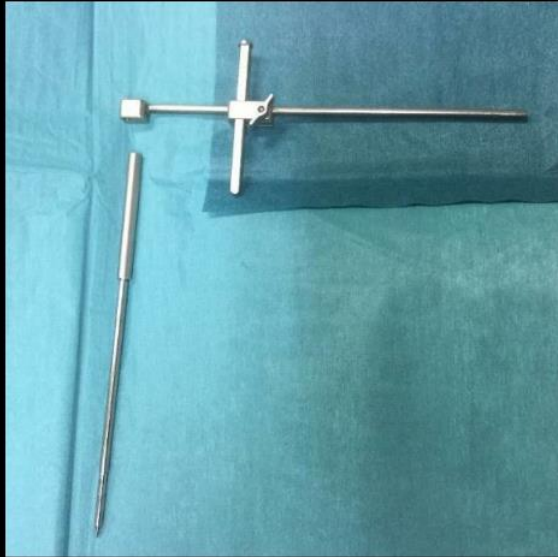Lunghezza e Offset



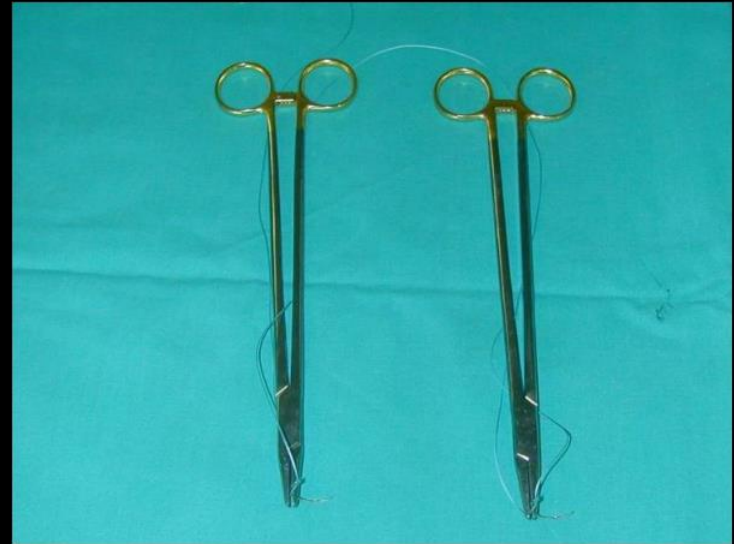VERIFICA INTRAOPERATORIA:

Lunghezza e Offset

METODO STRUMENTALE



METODO EMPIRICO



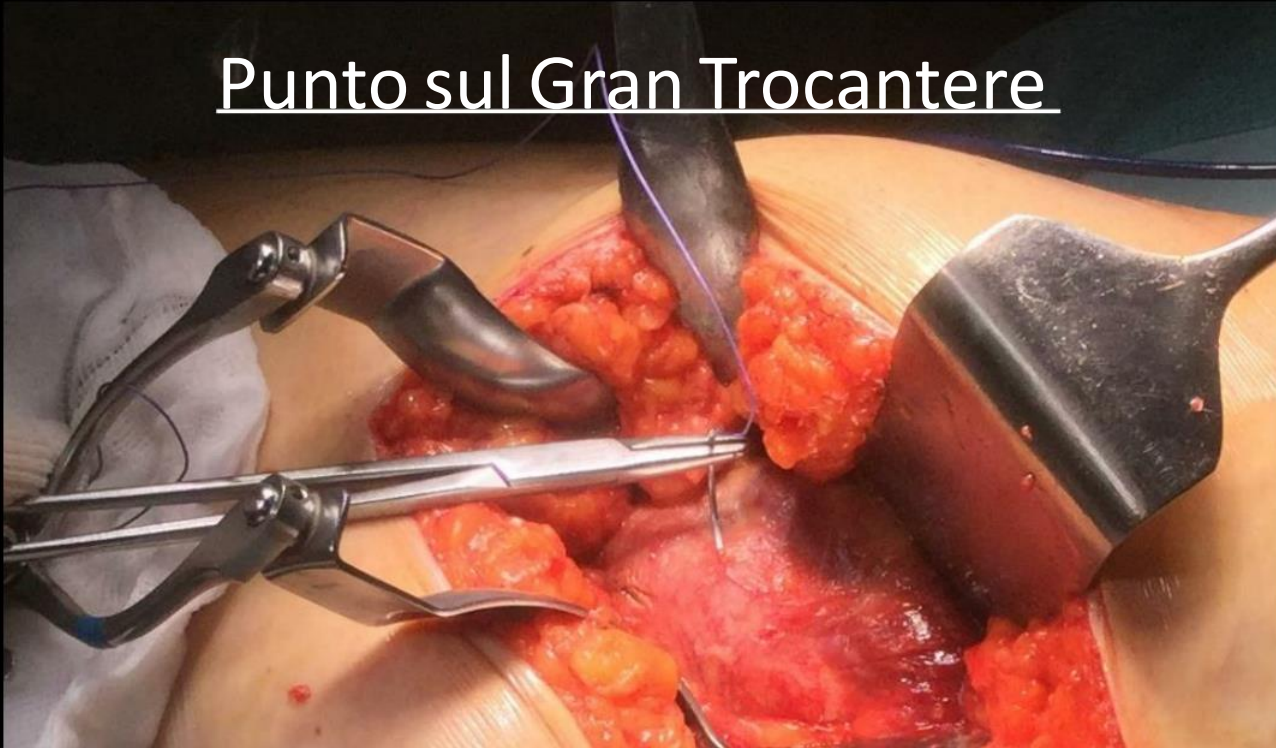VERIFICA INTRAOPERATORIA:

Lunghezza e Offset

METODO STRUMENTALE

METODO EMPIRICO

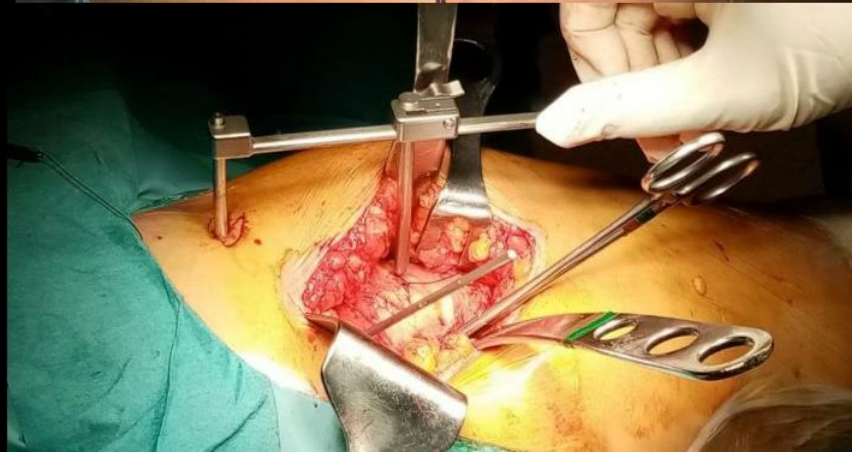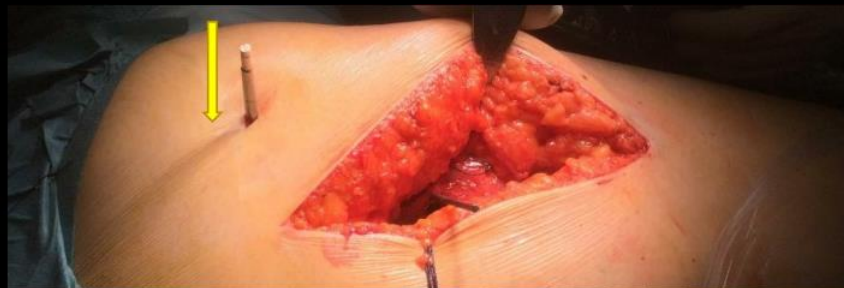Punto sul Gran Trocantere



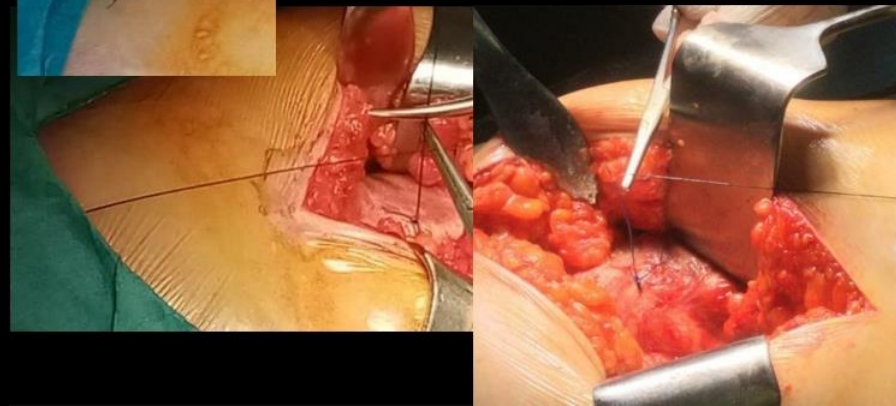
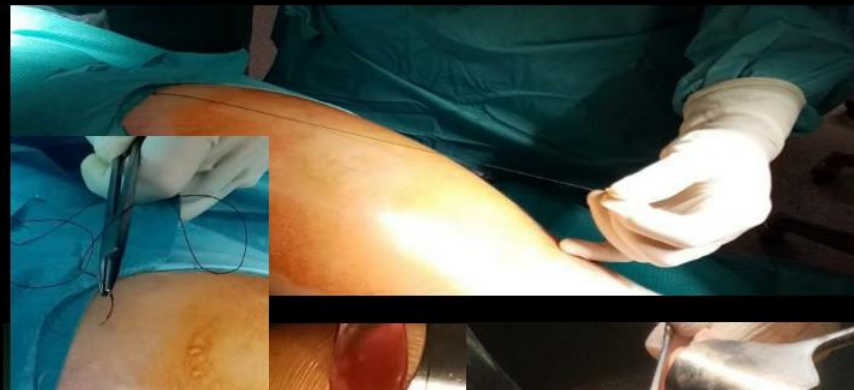VERIFICA INTRAOPERATORIA:

Lunghezza e Offset

METODO STRUMENTALE



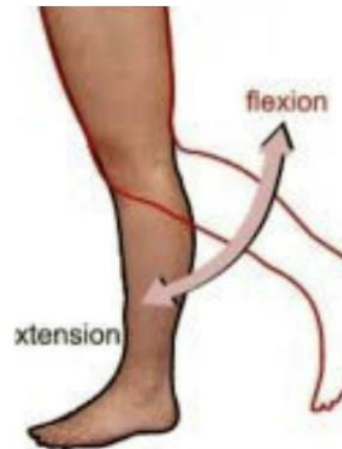
METODO EMPIRICO



COME VERIFICARE INTRAOPERATORIAMENTE L'ALLUNGAMENTO?


Kick Off test

If the leg is long...
the tibia will spontaneously kick forward on releasing the ankle



Misurazione Manuale

- Lunghezza alle ginocchia (rotula)
- Lunghezza ai malleoli



Cosa Dice La Letteratura.....

Original research article

Hip surgeons and leg length inequality after primary hip replacement

Faye A Loughenbury¹, Anthony B McWilliams^{1,2}, Todd D Stewart^{1,3}, Anthony C Redmond^{1,3} and Martin H Stone^{1,3}

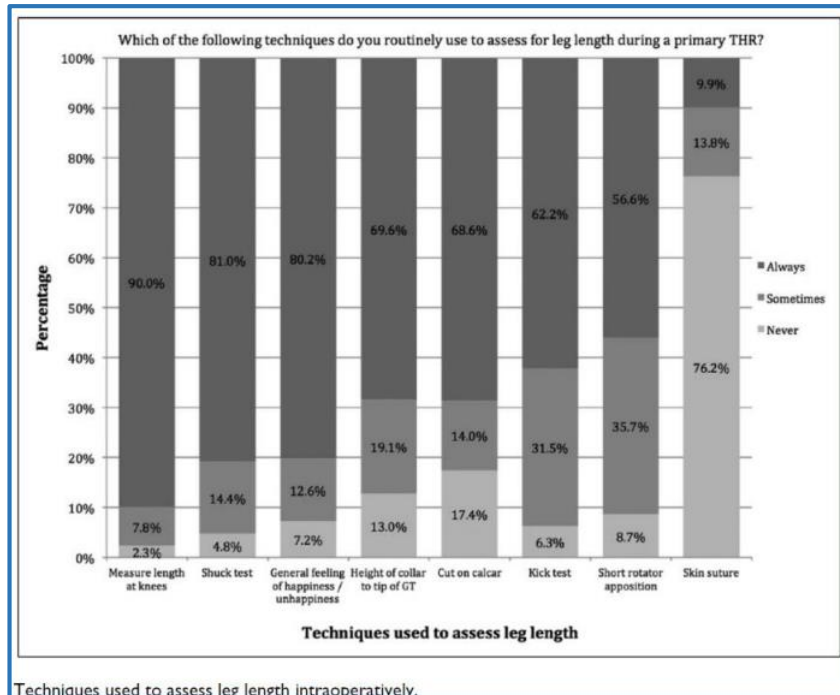
HIP
International

HIP International
2019, Vol. 29(1) 102–108
© The Author(s) 2018
Article reuse guidelines:
sagepub.com/journals-permissions
DOI: 10.1177/1120700918777858
journals.sagepub.com/home/hipi
SAGE

- All surgeons reported using at least 1 intraoperative technique for assessing leg length with a median of 5 techniques.

- Over 50% of surgeons use 2 or more tests

- The fact that more than 1 technique is used suggests that no single technique is completely accurate.....



- Utilizzare più di 1 Tecnica consente maggiore precisione!

Amplificatore di brillantezza

NO



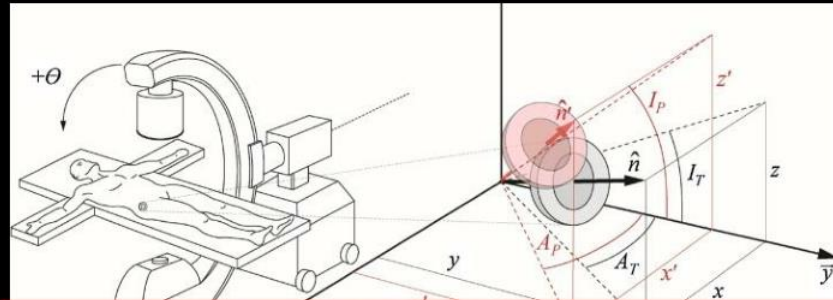
Clin Orthop Relat Res. 2014 Jun;472(6):1877-85. doi: 10.1007/s11999-014-3512-2. Epub 2014 Feb 19.

Does fluoroscopy with anterior hip arthroplasty decrease acetabular cup variability compared with a nonguided posterior approach?

Rathod PA¹, Bhalla S, Deshmukh AJ, Rodriguez JA.

CONCLUSIONS: Use of fluoroscopy with the patient in the supine position during direct anterior THA enables intraoperative assessment of cup orientation resulting in decreased variability of acetabular cup anteversion. However, there is a learning curve associated with achieving this accuracy. We could not discern whether this difference was the result of the approach or the use of fluoroscopy in the direct anterior group.

LEVEL OF EVIDENCE: Level III, therapeutic study. See the Instructions for Authors for a complete description of levels of evidence.



J Orthop. 2018 Mar 27;15(2):447-449. doi: 10.1016/j.jor.2018.03.036. eCollection 2018 Jun.

The effect of c-arm tilt on accuracy of intraoperative fluoroscopy in assessing acetabular component position during direct anterior approach for hip arthroplasty.

Jang ES¹, Lin JD¹, Shah RP¹, Geller JA¹, Cooper HJ¹.

La posizione del
C-arm può
influenzare
negativamente

Amplificatore di brillantezza

NO

Review

W

J Bone Joint Surg Am. 2016 Sep 7;98(17):e72. doi: 10.2106/JBJS.15.01080.

Surgeons' Accuracy in Achieving Their Desired Acetabular Component Orientation.

Grammatopoulos G¹, Alvand A², Monk AP², Mellon S³, Pandit H², Rees J², Gill HS⁴, Murray DW².

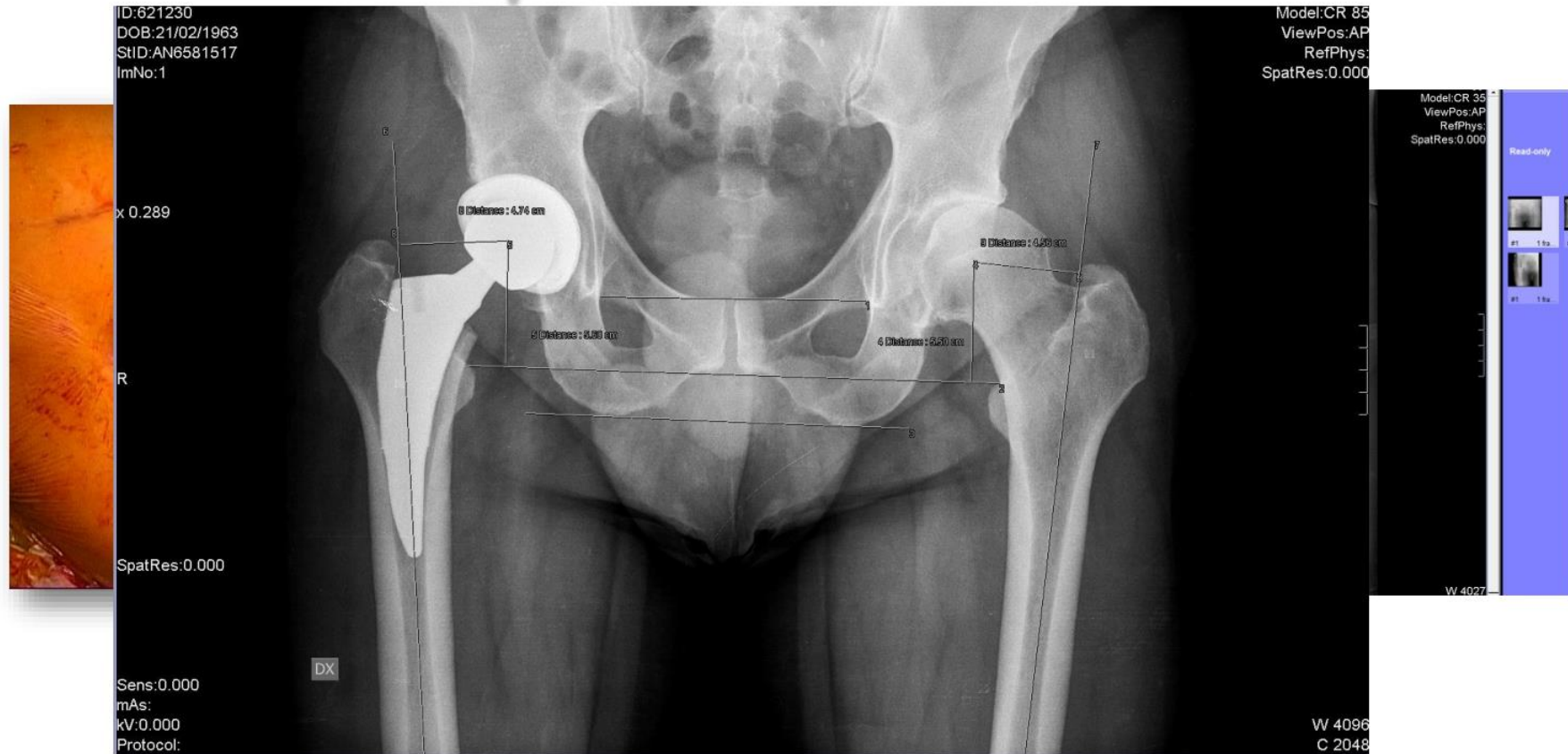
Author information

- 1 Nuffield Orthopaedic Centre, Oxford, United Kingdom Nuffield Department of Orthopaedics, Rheumatology & Musculoskeletal Sciences, Headington, Oxford, United Kingdom george.grammatopoulos@ndorms.ox.ac.uk.
- 2 Nuffield Orthopaedic Centre, Oxford, United Kingdom Nuffield Department of Orthopaedics, Rheumatology & Musculoskeletal Sciences, Headington, Oxford, United Kingdom.
- 3 Nuffield Department of Orthopaedics, Rheumatology & Musculoskeletal Sciences, Headington, Oxford, United Kingdom.
- 4 Department of Mechanical Engineering, University of Bath, Bath, United Kingdom.

L'esperienza del chirurgo è il principale fattore di influenza

CONCLUSIONS: Surgeons overestimate the operative inclination and underestimate anteversion, which is of benefit, as this, on average, helps to achieve the desired radiographic cup orientation. Although the use of visual cues helps, conventional techniques result in a large variability in acetabular component orientation. New and better guides and methods for training need to be developed.

Via Antero-laterale: Amplificatore di brillantezza



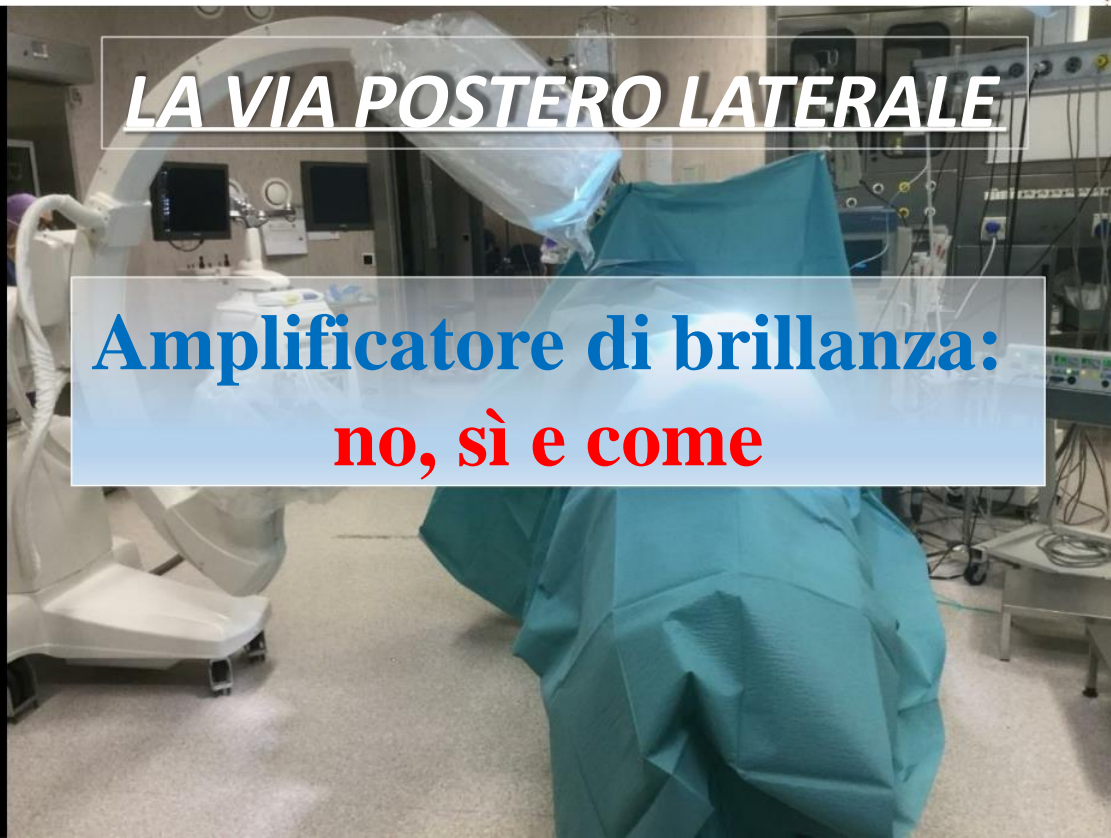

CONGRESSO NAZIONALE DELLA
SOCIETÀ ITALIANA DELL'ANCA

19-20
settembre 2019
BERGAMO

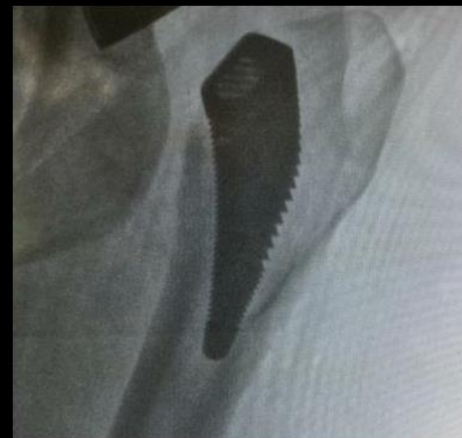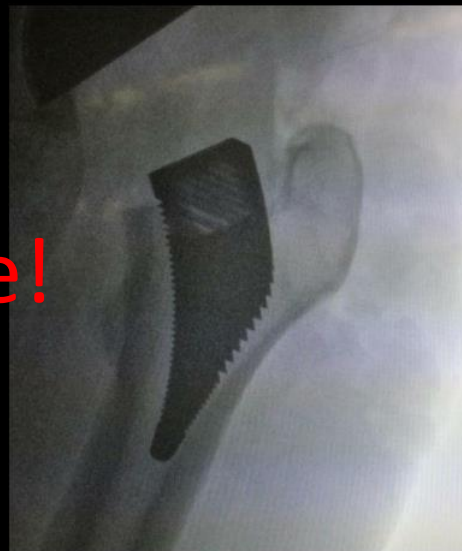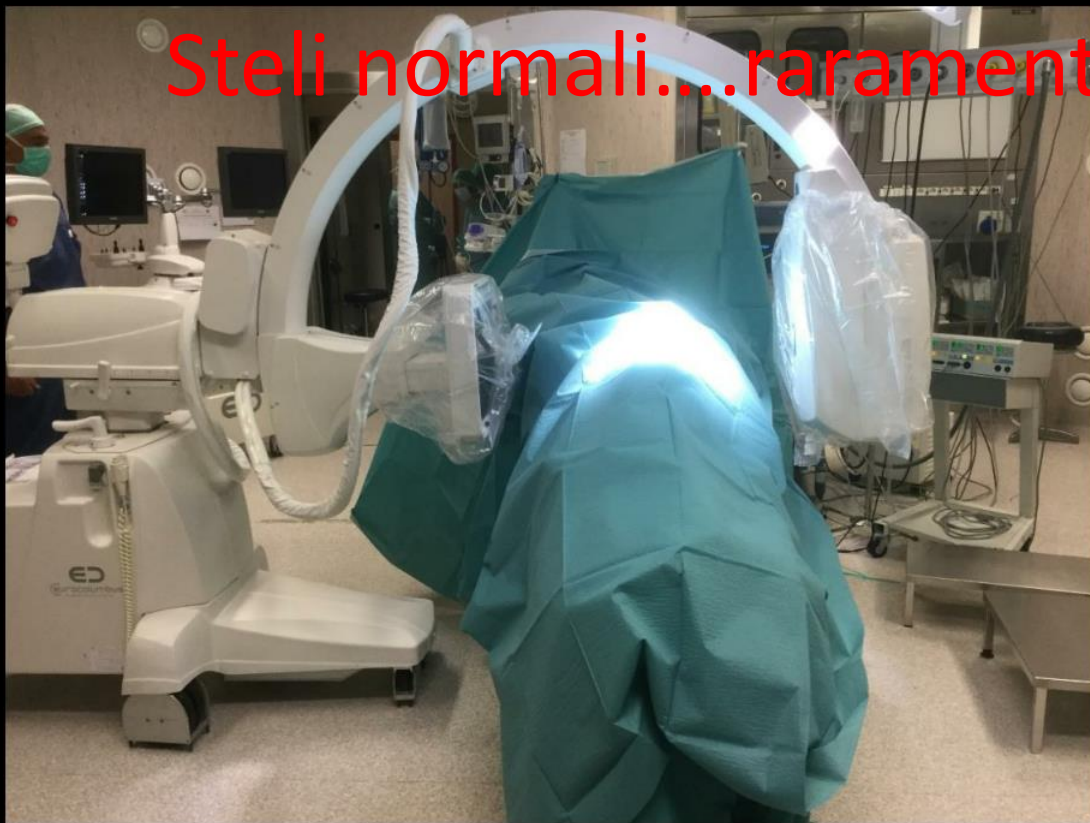LA VIA POSTERO LATERALE

**Amplificatore di brillantezza:
no, sì e come**



.....Steli corti....Sempre!

Steli normali....raramente!



Cosa Dice La Letteratura.....Amplificatore di brillantezza?



■ HIP ARTHROPLASTY: MANAGEMENT FACTORIALS

Intra-operative digital imaging

ASSURING THE ALIGNMENT OF COMPONENTS WHEN UNDERTAKING TOTAL HIP ARTHROPLASTY

D. Hambright,
M. Hellman,
R. Barrack

From Washington
University School of
Medicine, Barnes-
Jewish Hospital,
Missouri, United
States

Aims

The aims of this study were to examine the rate at which the positioning of the acetabular component, leg length discrepancy and femoral offset are outside an acceptable range in total hip arthroplasties (THAs) which either do or do not involve the use of intra-operative digital imaging.

- Intraoperative imaging requires additional resources and can increase operating time.

for surgery. The digital imaging group had more men than the group without. Surgical data

- The mean duration of intraoperative imaging has been reported to be..
...5 minutes....

Digital imaging took a mean of five minutes (2.3 to 14.6) to perform. Intra-operative changes with the use of digital imaging were made for 43 patients (86%), most commonly to adjust leg length and femoral offset. There was a decrease in the incidence of outliers when using intra-operative imaging compared with not using it in regard to leg length discrepancy (20% *versus* 52%, $p = 0.001$) and femoral offset inequality (18% *versus* 44%, $p = 0.004$). There was also a difference in the incidence of outliers in acetabular inclination (0% *versus* 7%, $p = 0.023$) and version (0% *versus* 4%, $p = 0.114$) compared with historical results of a high-volume surgeon at the same centre.

Conclusion

The use of intra-operative digital imaging in THA improves the accuracy of the positioning of the components at THA without adding a substantial amount of time to the operation.

Cite this article: *Bone Joint J* 2018;100B(1 Supple A):36-43.

© D. Hambright, MD,
Orthopaedic Surgery Fellow,
Department of Orthopaedic
Surgery, Washington
University School of Medicine
Barnes-Jewish Hospital, 660
South Euclid, Campus Box
8233, St. Louis, MO 63110, USA.

© M. Hellman, MD,

Limb length= 20%vs
50%
Off set=%vs 44%

Inclination=0%vs 7%
Anteversion=0%vs 7%

Cosa Dice La Letteratura.....Amplificatore di brillantezza?



■ THE HIP SOCIETY

Changes in acetabular orientation during total hip arthroplasty

**D. T. Schloemann,
A. I. Edelstein,
R. L. Barrack**

*From Washington
University School
of Medicine,
St. Louis, Missouri,
United States*

~~- intraoperative imaging ...allows identification of pelvic changes....~~

- ...and may dramatically decrease the incidence of malpositioning of the component!

Beamer BS, Morgan JH, Barr C, Weaver MJ, Vrahas MS. Does fluoroscopy improve acetabular component placement in total hip arthroplasty? *Clin Orthop Relat Res* 2014;472:3953–3962.

Penenberg BL, Woehni A. Intraoperative digital radiography: an opportunity to assure. *Seminars in Arthroplasty* 2014;25:130–134.

Penenberg BL, Samagh SP, Rajae SS, Woehni A, Brien WW. Digital radiography in total hip arthroplasty: technique and radiographic results. *J Bone Joint Surg [Am]* 2018;100-A:226–235.

NO

[Clin Orthop Relat Res.](#) 2015 Nov; 473(11): 3401–3408.

Published online 2015 Mar 12. doi: [10.1007/s11999-015-4230-0](#)

PMCID: PMC4586236

PMID: [25762014](#)

Anterior and Anterolateral Approaches for THA Are Associated With Lower Dislocation Risk Without Higher Revision Risk

[Dhiren Sheth](#), MD, [Guy Cafri](#), PhD, [Maria C. S. Inacio](#), PhD,[✉] [Elizabeth W. Paxton](#), MA, and [Robert S. Namba](#), MD

[Clin Orthop Relat Res.](#) 2006 Jun;447:34-8.

Does surgical approach affect total hip arthroplasty dislocation rates?

[Kwon MS](#)¹, [Kuskowski M](#), [Mulhall KJ](#), [Macaulay W](#), [Brown TE](#), [Saleh KJ](#).

✉ Author information

1 Department of Orthopaedic Surgery, University of Virginia, Charlottesville, VA, USA.

[J Arthroplasty.](#) 2015 Mar;30(3):419-34. doi: [10.1016/j.arth.2014.10.020](#). Epub 2014 Oct 22.

Anterior vs. posterior approach for total hip arthroplasty, a systematic review and meta-analysis.

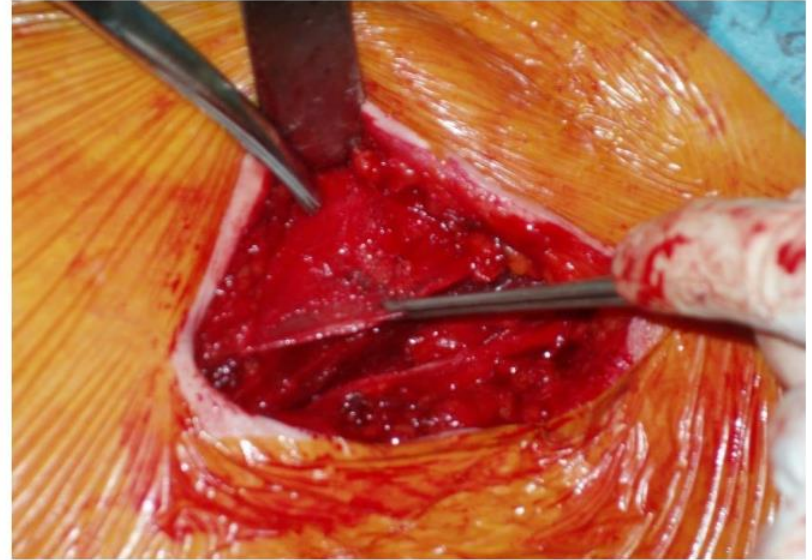
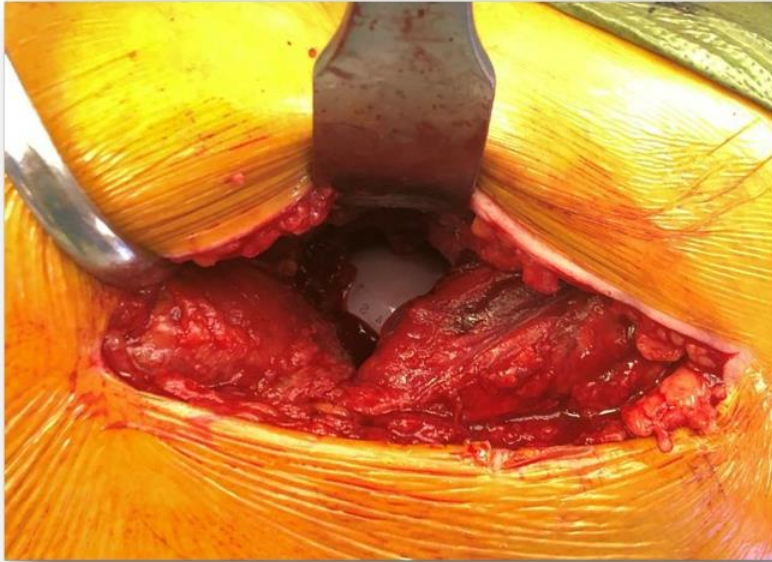[Higgins BT](#)¹, [Barlow DR](#)², [Heagerty NE](#)³, [Lin TJ](#)¹.

✉ Author information

- 1 Department of Orthopaedic Surgery, Dartmouth Hitchcock Medical Center, Lebanon, New Hampshire; The Dartmouth Institute for Health Policy and Clinical Practice, Lebanon, New Hampshire.
- 2 The Dartmouth Institute for Health Policy and Clinical Practice, Lebanon, New Hampshire; Geisel School of Medicine at Dartmouth, Hanover, New Hampshire.
- 3 The Dartmouth Institute for Health Policy and Clinical Practice, Lebanon, New Hampshire.

Il vantaggio della sutura capsulare è dimostrato essere un minor tasso di lussazione.

Via Antero-laterale: Sutura capsulare



Non eseguiamo nessuna sutura capsulare (Rischio contrattura in flessione)
Non eseguiamo nessuna sutura capsulare (Rischio contrattura in flessione)



CONGRESSO NAZIONALE DELLA
SOCIETÀ ITALIANA DELL'ANCA



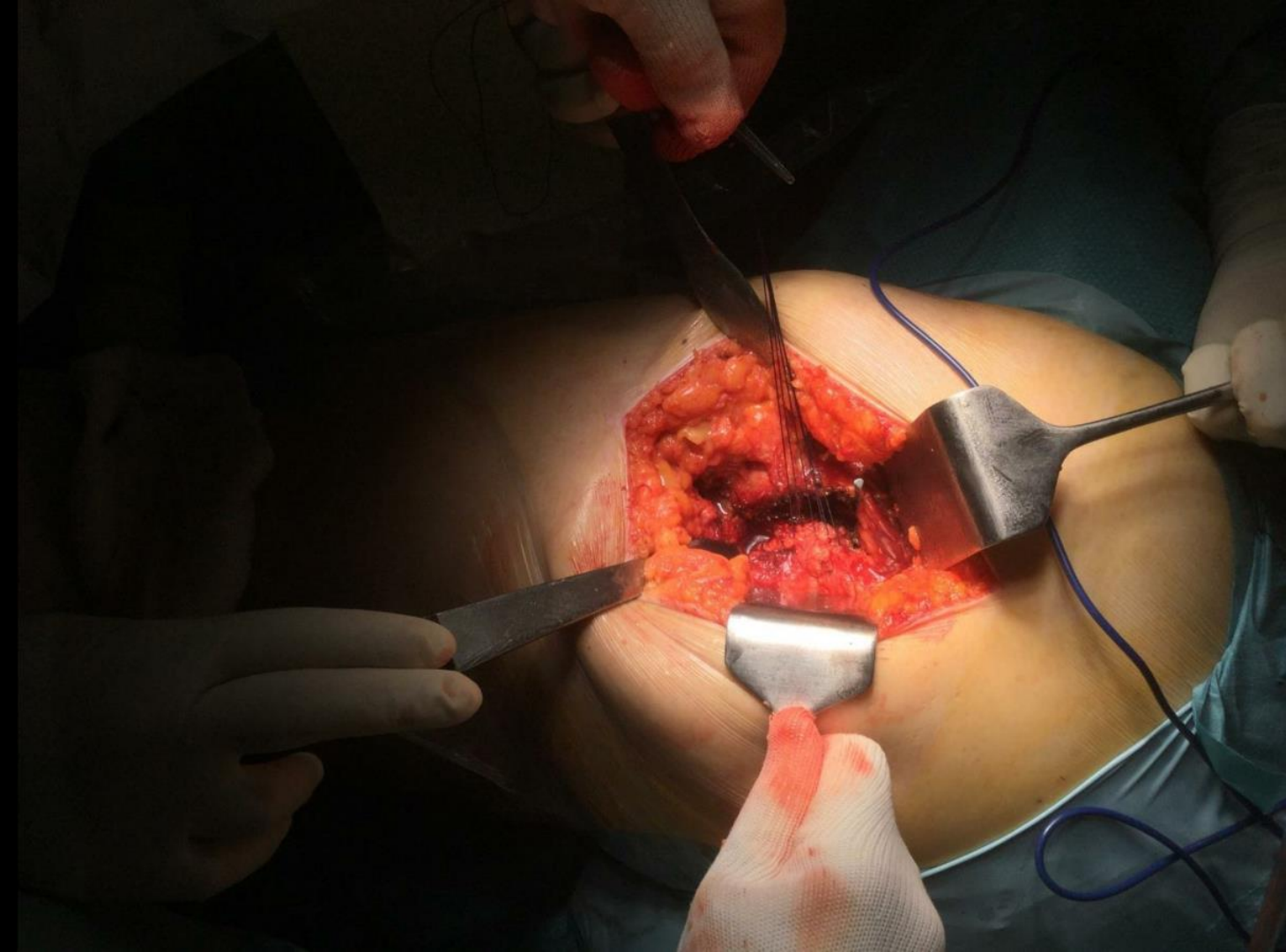
19-20

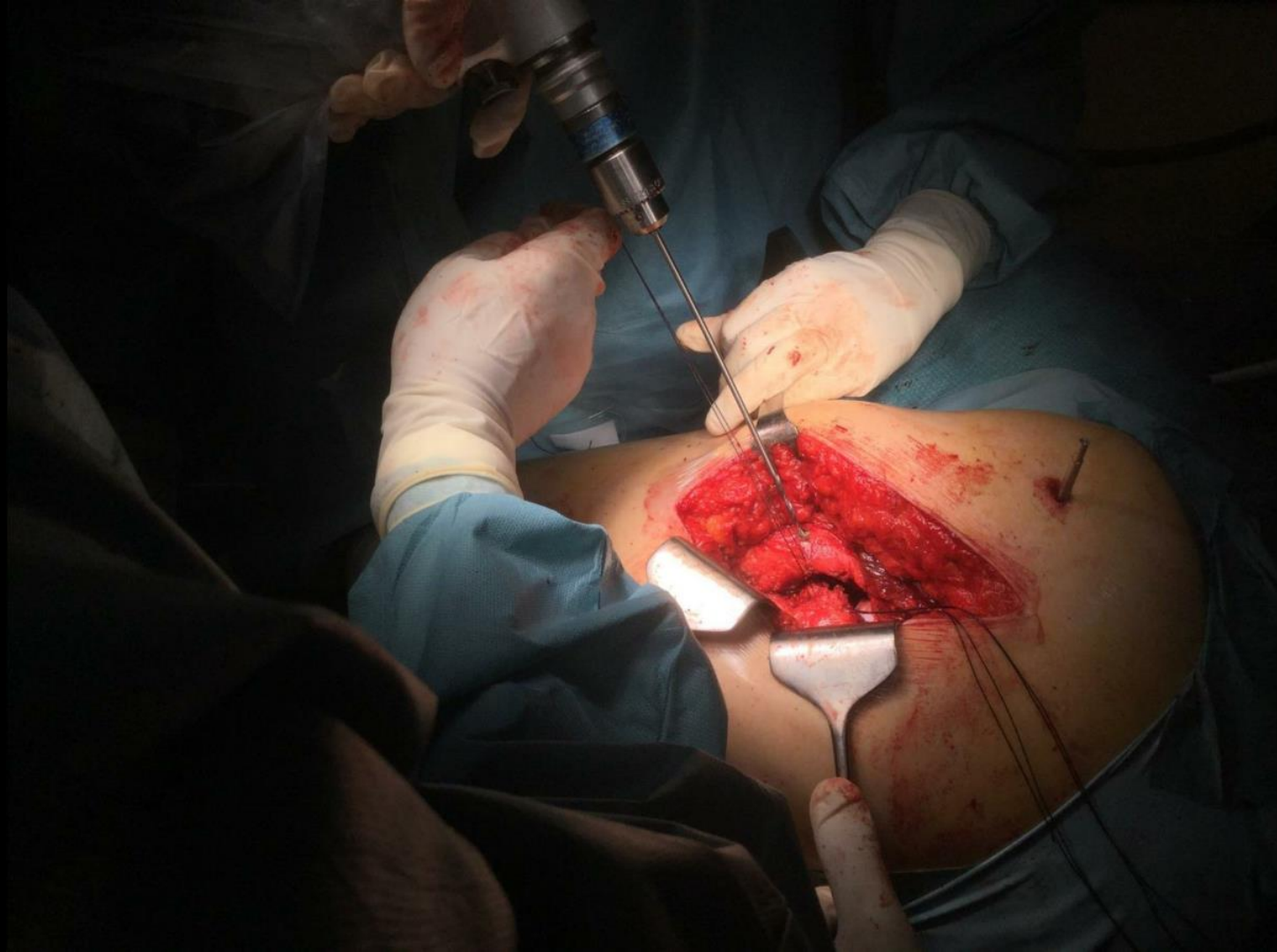settembre 2019

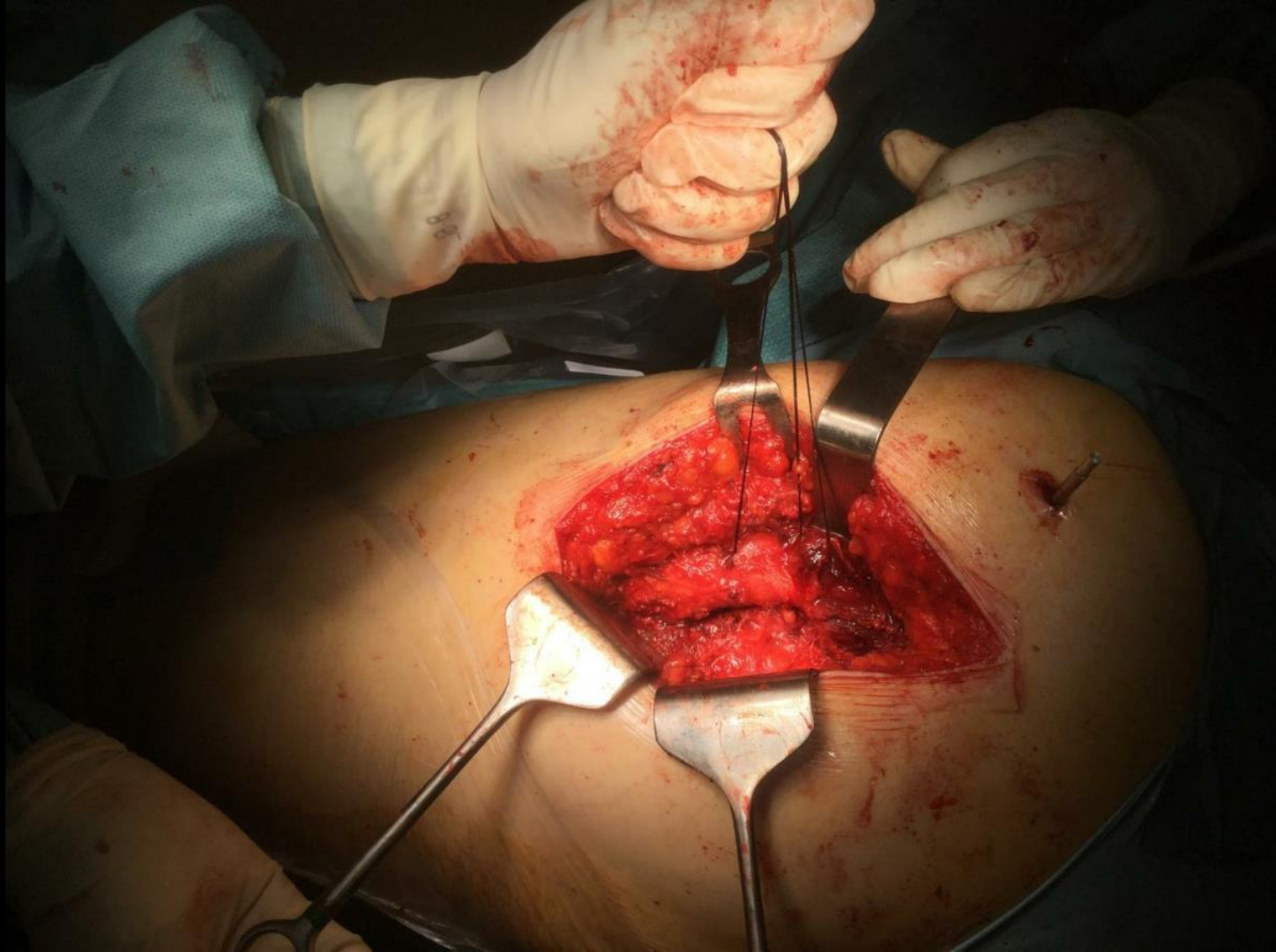
BERGAMO

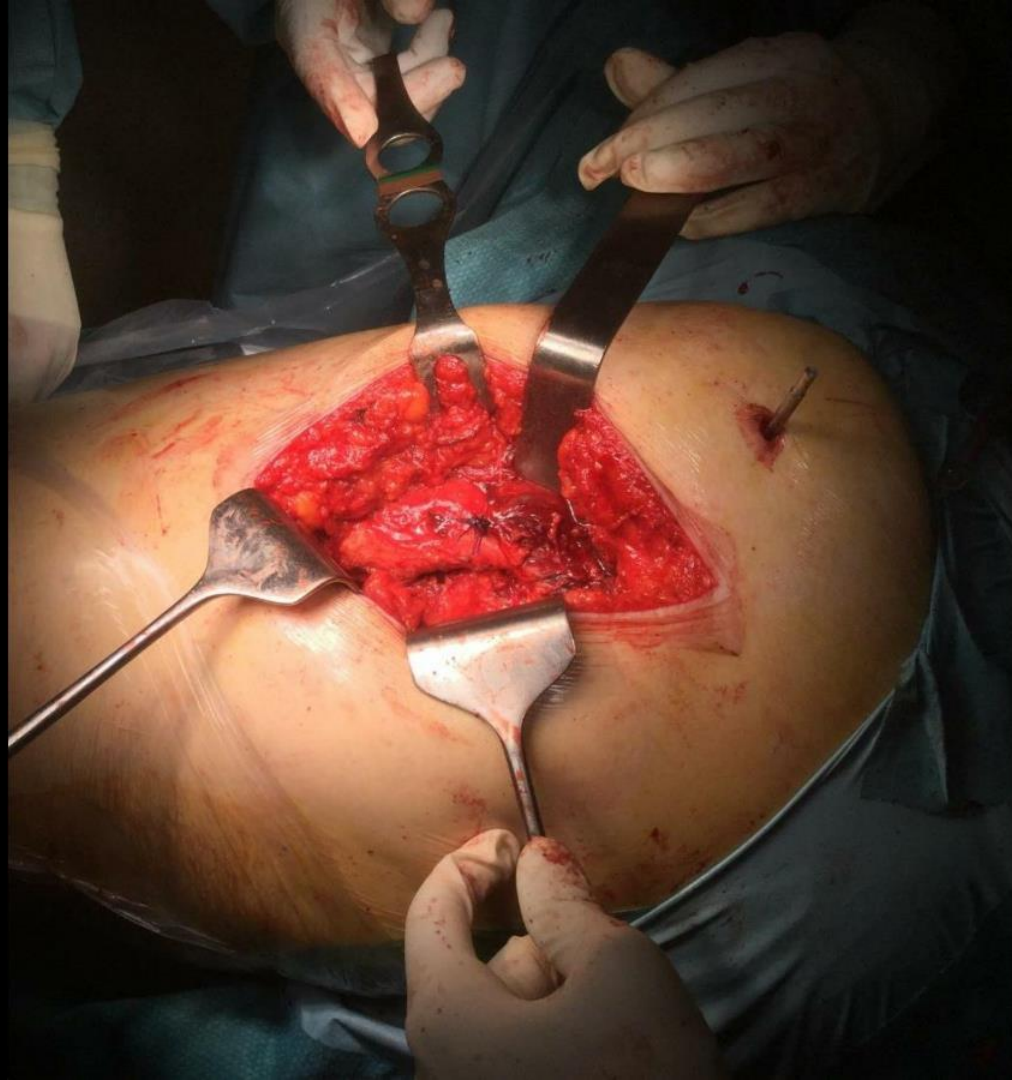
LA VIA POSTERO LATERALE

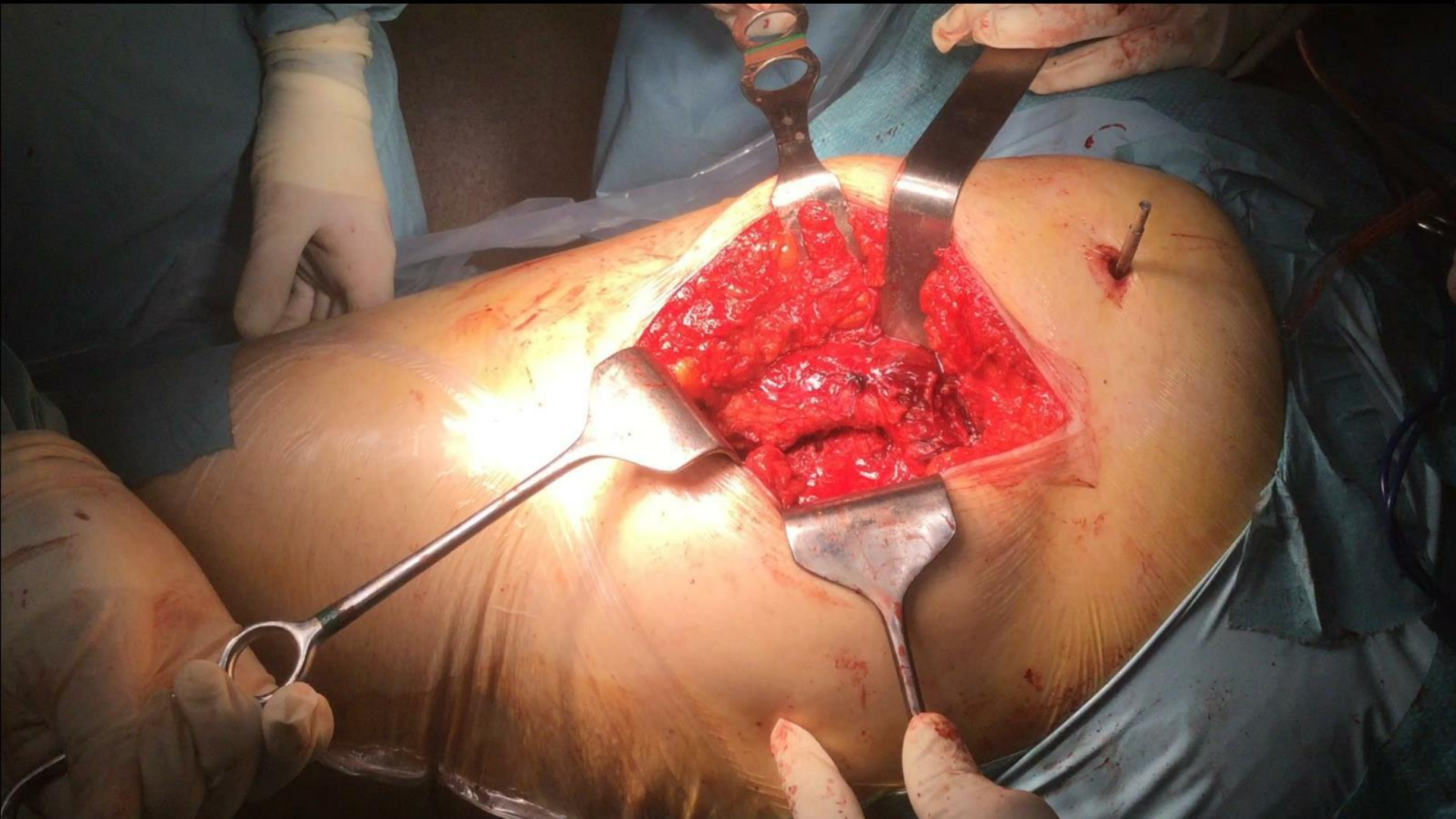
SUTURA CAPSULARE:
No, Sì e Come











Cosa Dice La Letteratura.....

HSSJ (2006) 2: 7-11
DOI 10.1007/s11420-005-0134-y

REVIEW ARTICLE

Review: Posterior Soft Tissue Repair in Primary Total Hip Arthroplasty

F. Bottner, MD • P. M. Pellicci, MD

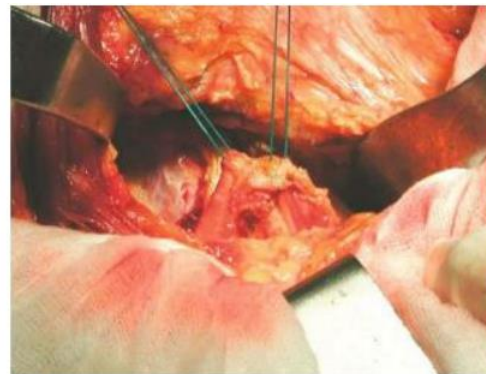


Fig. 2. Ethibond tagging sutures are placed in the short external rotators

Dislocation in Posterior approach
may be avoid

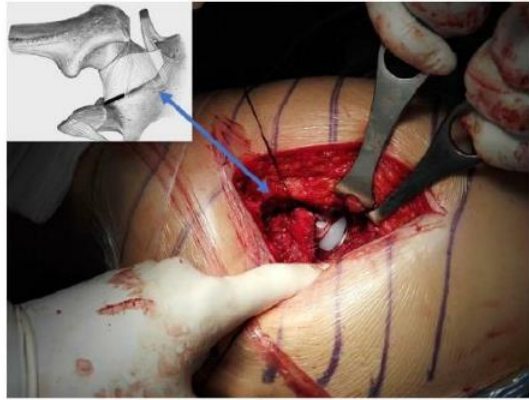.....using Enhanced Posterior Soft Tissue Repair

P.M. Pellicci et al., CORR,

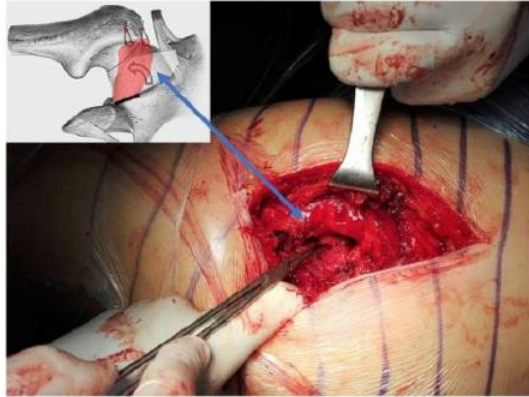
Tension-free closure with capsular lengthening in mini posterior total hip replacement

Nicola Santori

HIP International 2018, Vol. 28(2S) 3–9

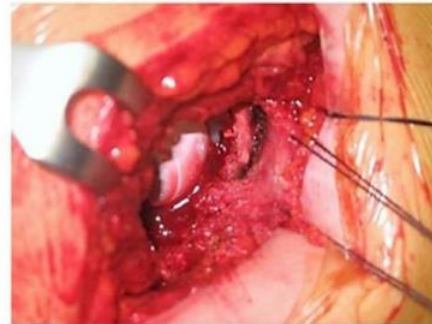

(a)

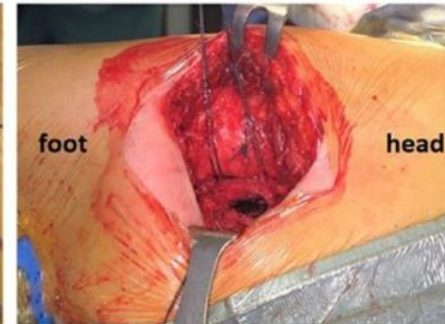

(b)

Figure 4. Distal based capsular shift technique. (a) a strip of retracted capsule is detached from the upper posterior acetabular margin (b) a 2nd stitch is applied to capsular margin and the strip is rotated and inserted onto the greater trochanter.



(a)



(b)

Figure 3. Inside-out bucket-handle capsular lengthening technique. (a) Partial inside-out capsulectomy preserving proximal and distal capsular insertions on the acetabulum. (b) Adequate approximation to the greater trochanter of the lengthened posterior envelope with 45° of hip flexion and 30° of internal rotation. The piriformis tendon is fixed on the gluteus medius close to the tip of the greater trochanter.

Regime e Restrizioni post-operatorie

VALUTAZIONE DELL'EFFICACIA DEL PROTOCOLLO FAST-TRACK NELL'ARTROPROTESI D'ANCA VS PROTOCOLLO "STANDARD CARE" NELLA RIDUZIONE DELLA DEGENZA OSPEDALIERA E NELLA RIPRESA DEL CARICO PRECOCE: STUDIO RANDOMIZZATO CONTROLLATO



CONGRESSO NAZIONALE DELLA
SOCIETÀ ITALIANA DELL'ANCA

19-20
settembre 2019
BERGAMO

SALA B

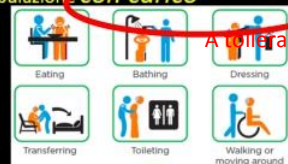09.00 COMUNICAZIONI ORALI 6 (cont.)
10.00

Studio randomizzato controllato sull'efficacia del protocollo fast track vs protocollo "standard care" nel recupero funzionale precoce in protesica d'anca

Martina Rocchi, Cesare Stagni, Alessandro Mazzotta, Giuseppe Di Sante, Dante Dallari (Bologna)

• **Giorno 3**

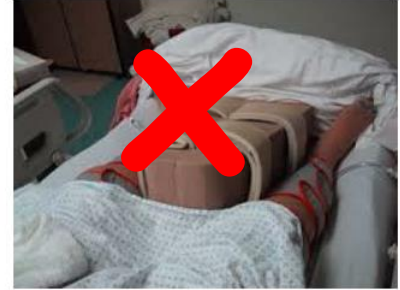- ✓ Autonomia BADL (Attività di Base della Vita Quotidiana)
- ✓ Autonomia trasferimenti letto-poltrona
- ✓ Autonomia spostamenti in bagno
- ✓ Deambulazione **con carico**



DIMISSIONE

Via Antero-laterale:
Regime e restrizioni post-operatorie immediate

Nessuna tutore o restrizione di posizione



Nessun presidio a domicilio

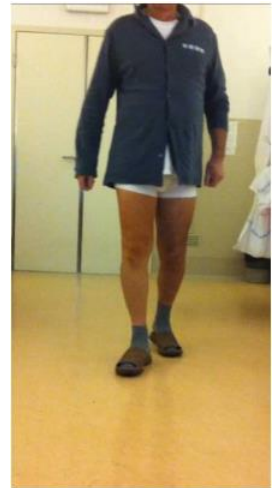

Via Antero-laterale:

Regime e restrizioni post-operatorie immediate

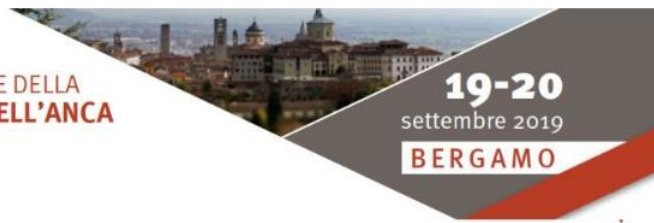Limitare adduzione ed extrarotazione combinate

Carico post-operatorio completo, come tollerato, dal I° giorno post-op.





CONGRESSO NAZIONALE DELLA
SOCIETÀ ITALIANA DELL'ANCA



19-20

settembre 2019

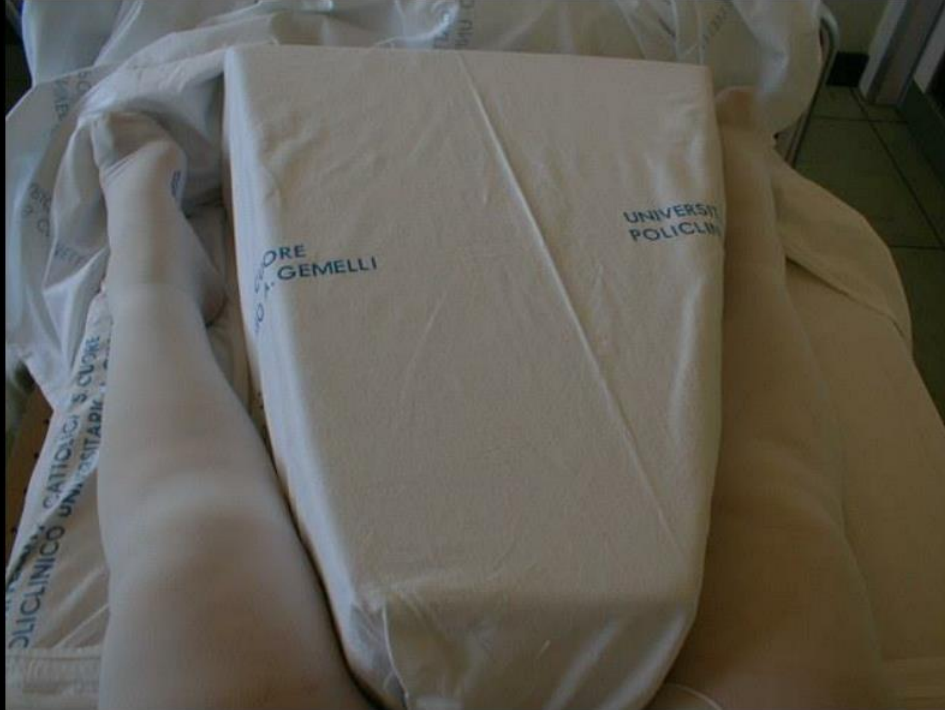BERGAMO

LA VIA POSTERO LATERALE

REGIME E RESTRIZIONI POST OPERATORIE IMMEDIATE:

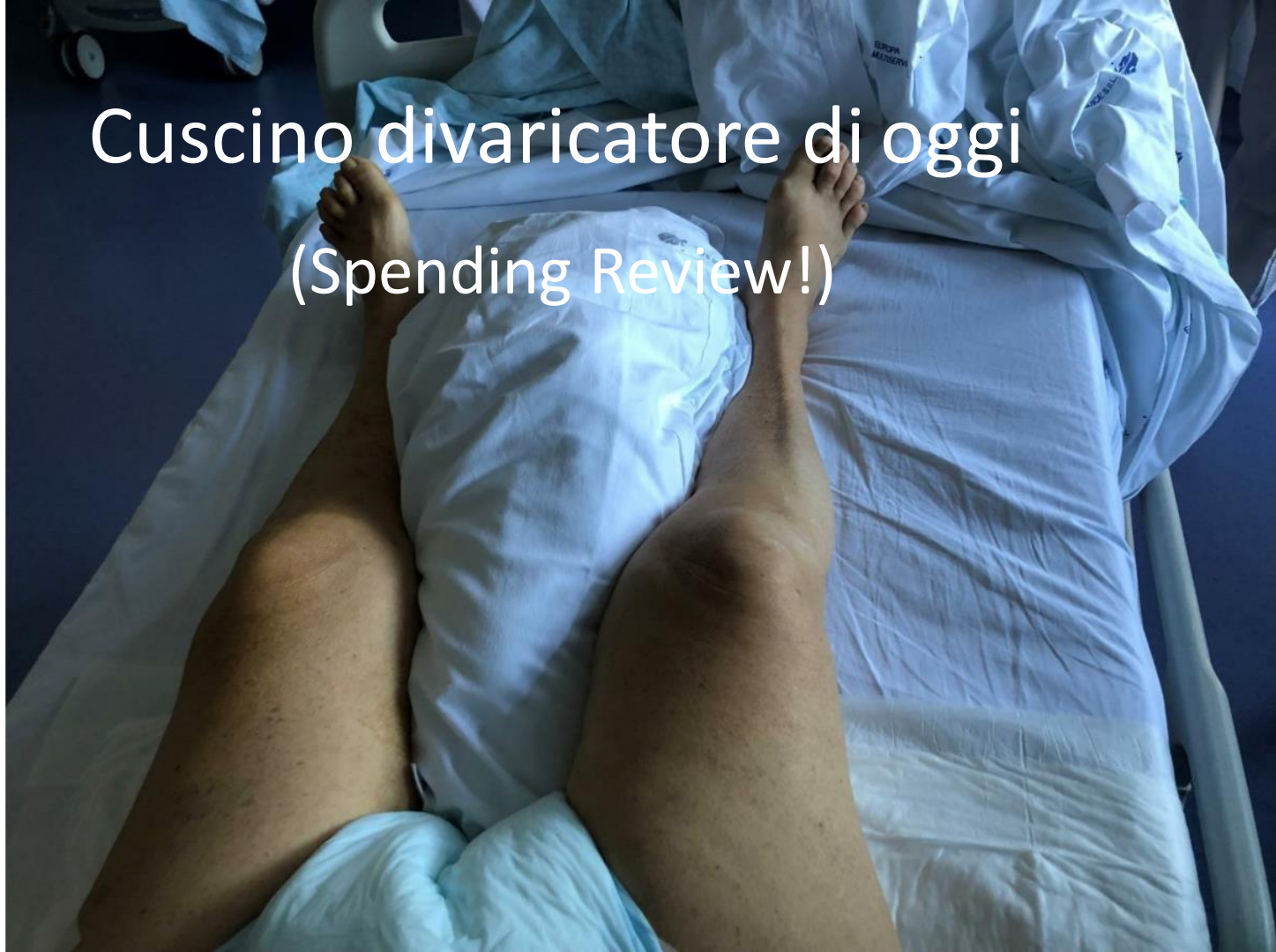No, Sì e Quali

Prime 3 settimane



Cuscino Divaricatore (quando eravamo ricchi!)

Cuscino divaricatore di oggi
(Spending Review!)



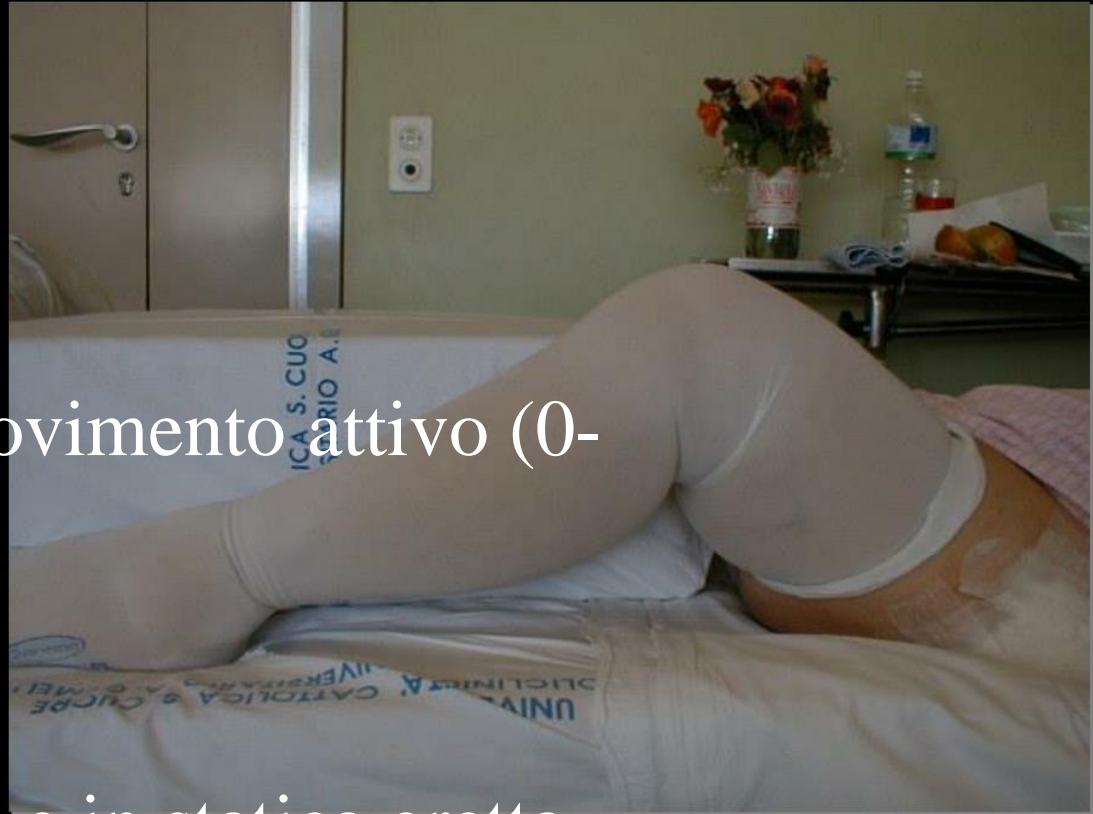Standard Protocol

Subito

- Contrazioni e movimento attivo (0-60°)

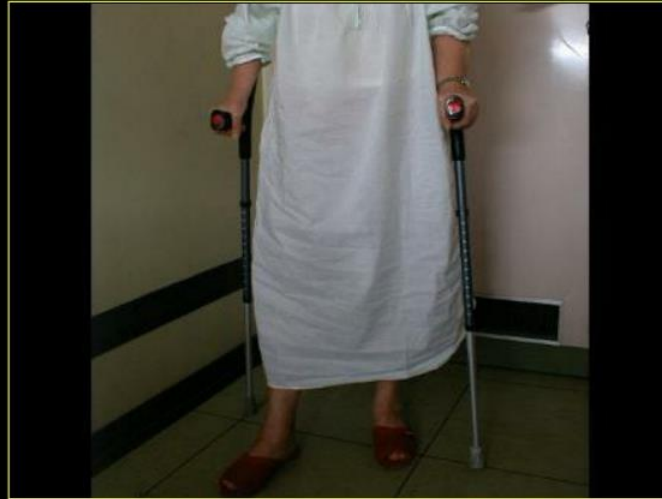I giorno post-op

- Seduta (< 90°) e in statica eretta



Prime 3 settimane

Deambulazione

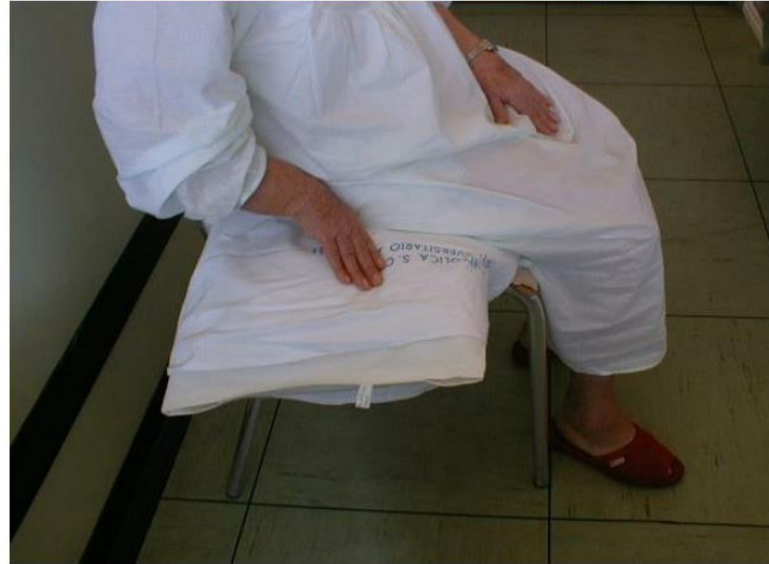
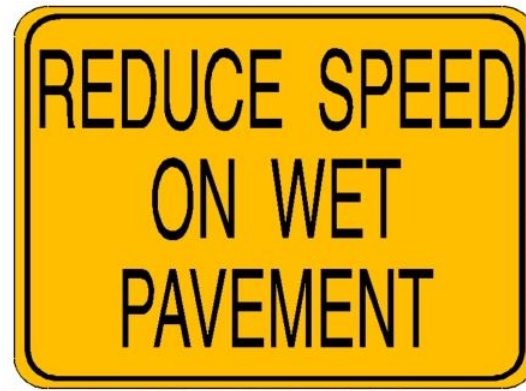
II giorno postop

- Deambulazione con carico graduale con Appoggi

Precauzioni

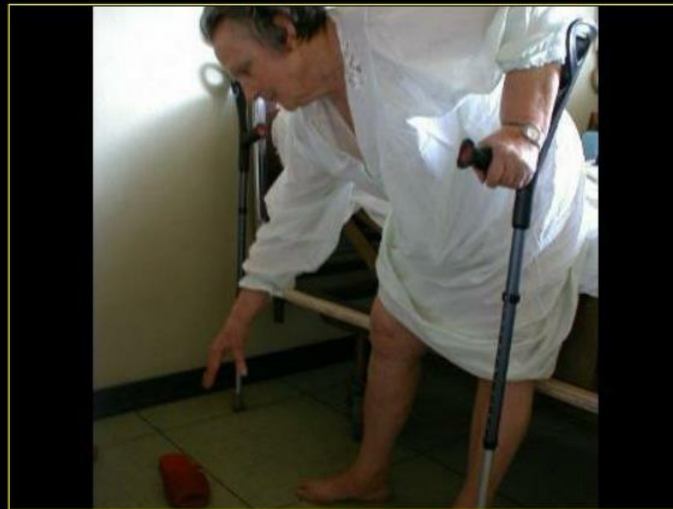- Rialzo per il water
- Seduta elevata
(Flessione $> 90^\circ$)



Posizioni Sconsigliate



- Flessione $> 90^\circ$
- Intrarotazione
- Adduzione



NON ACCAVALLARE LE GAMBE!

Collaborazione Medico di Base - Specialista

ATTENZIONE alle.... INFEZIONI

0.5 / 2 %

“Rischio di infezioni a seguito di manovre invasive ...”

(A. D. Hanssen et al., JBJS, 1996)


•*dentali , urologiche (endoscopia, cateterismo), cateterismo venoso*

Fare Profilassi antibiotica

Collaborazione Medico di Base - Specialista

Medico di Famiglia:

- *Scambio di informazioni riguardo il tipo di intervento*



Secondo mese Attività Consentite

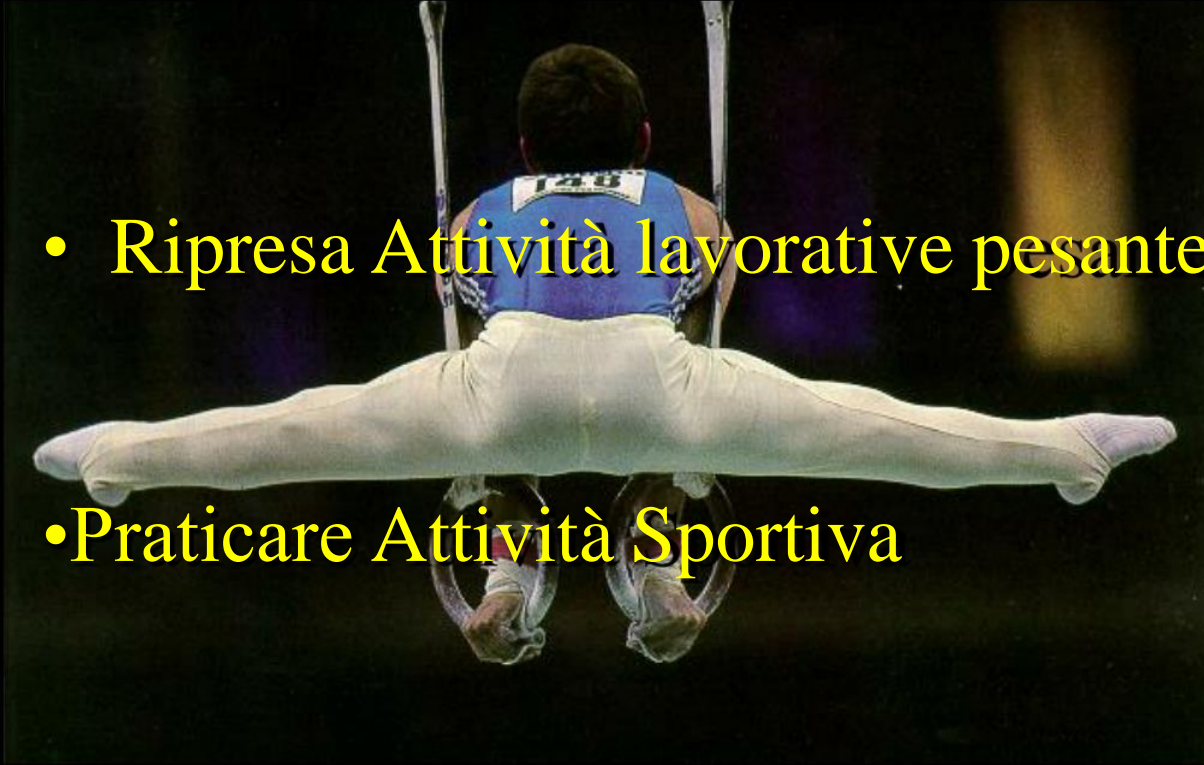- Guidare
- Nuoto
- Bicicletta
- Lavori leggeri



Terzo mese Attività Consentite

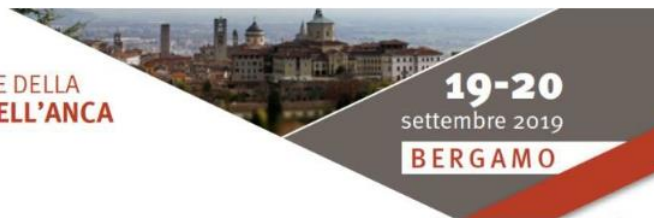- Ripresa Attività lavorative pesante

- Praticare Attività Sportiva





CONGRESSO NAZIONALE DELLA
SOCIETÀ ITALIANA DELL'ANCA



19-20

settembre 2019

BERGAMO

LE VIE DI ACCESSO NELLE PROTESI PRIMARIE LE OPINIONI E I DETTAGLI TECNICI: COME E PERCHÉ

GRAZIE

D. Dallari, R. Civinini, G. Logroscino



10.30 SIMPOSIO 1: LE VIE DI ACCESSO NELLE PROTESI PRIMARIE
12.00 Moderatori: **Vincenzo Salini** (Milano), **Giovanni Zatti** (Monza)
Anchorman: **Francesco Benazzo** (Pavia)

19 SETTEMBRE 2019
GIOVEDÌ

11.05
11.12

La via laterale diretta: è ancora attuale?
Filippo Casella (Roma)

11.12
11.35

Discussione

FATTI, IPOTESI E ILLUSIONI

11.35
11.45

L'informazione al paziente: chi, come
Luigi Zagra (Milano)

11.45
11.55

La letteratura e i registri: sopravvivenza, complicanze
e risultati a medio lungo termine
Emilio Romanini (Roma)

11.55
12.00

Fate quello che fate bene... ma fatelo molto bene
Francesco Benazzo (Pavia)



ROMA



19-20
settembre 2019

BERGAMO

Presidente Onorario
Paolo Cherubino

Presidente
Claudio Carlo Castelli

LA VIA LATERALE DIRETTA E' ANCORA ATTUALE?

FILIPPO CASELLA

PROGRAMMA



AUDITORIUM

10.30 SIMPOSIO 1: LE VIE DI ACCESSO NELLE PROTESI PRIMARIE
12.00 Moderatori: **Vincenzo Salini** (Milano), **Giovanni Zatti** (Monza)
Anchorman: **Francesco Benazzo** (Pavia)

10.30 LE OPINIONI E I DETTAGLI TECNICI: COME E PERCHÉ
11.05 Via anteriore diretta - **Dante Dallari** (Bologna)
Via antero laterale - **Roberto Civinini** (Firenze)
Via postero laterale - **Giandomenico Logroscino** (L'Aquila)

10.30 Set-up: letto chirurgico, posizione del paziente e supporti
10.36 **Dante Dallari** (2°),
Roberto Civinini (2°),
Giandomenico Logroscino (2°)

10.36 Esposizione acetabolare: circonferenziale o buco della serratura?
10.42 **Dante Dallari** (2°),
Roberto Civinini (2°),
Giandomenico Logroscino (2°)

10.42 Esposizione femore prossimale: risparmio trocanterico e abductori,
10.51 accesso e preparazione canale midollare
Dante Dallari (3°),
Roberto Civinini (3°),
Giandomenico Logroscino (3°)

Verifica intraoperatoria lunghezza
Dante Dallari (2°),
Roberto Civinini (2°),
Giandomenico Logroscino (2°)

Amplificatore di brillantezza
Dante Dallari (30°),
Roberto Civinini (30°),
Giandomenico Logroscino (30°)

Artroscopia capsulare (non)
Dante Dallari (5°),
Roberto Civinini (5°),
Giandomenico Logroscino (5°)

Dante Dallari (5°),
Giandomenico Logroscino (5°)



GIOVEDÌ
19 SETTEMBRE 2019



10.30 SIMPOSIO 1: LE VIE DI ACCESSO NELLE PROTESI PRIMARIE
12.00 (cont.)

11.05 La via laterale diretta: è ancora attuale?
11.12 **Filippo Casella** (Roma)

11.12 Discussione
11.35

FATTI, IPOTESI E ILLUSIONI

11.35 L'informazione al paziente: chi, come
11.45 **Luigi Zagra** (Milano)

11.45 La letteratura e i registri: sopravvivenza, complicanze
11.55 e risultati a medio lungo termine
Emilio Romanini (Roma)

11.55 Fate quello che fate bene... ma fate lo molto bene
12.00 **Francesco Benazzo** (Pavia)

12.00 SIMPOSIO AZIENDALE
13.00 LINK&HERAEUS & MEDICAD
(vedi pagina 34)

12.00 WORKSHOP AZIENDALE
12.30 NORMEDITEC
(vedi pagina 34)

13.00 Lunch
13.30

SALA A

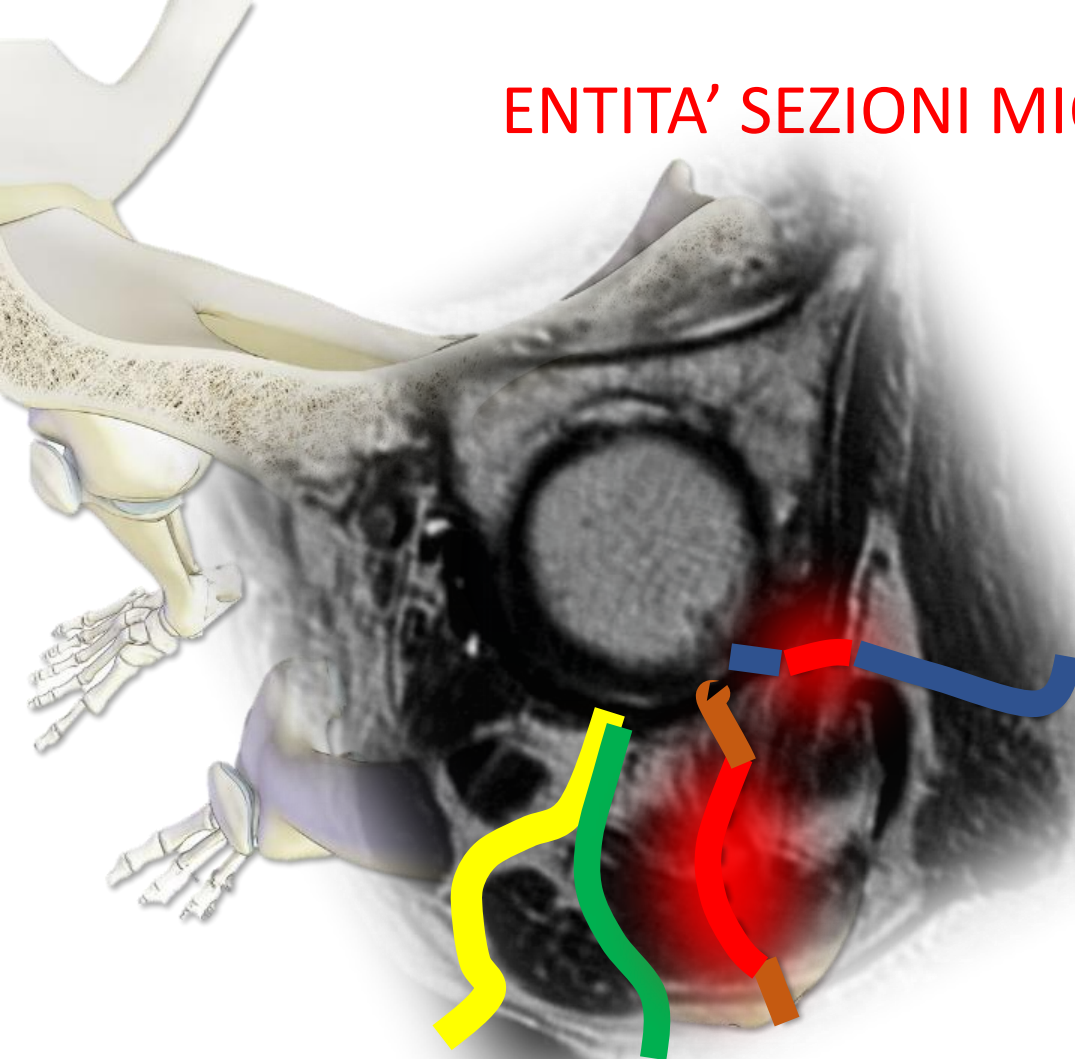SALA B



QUAL'E' IL PERCHE' DI QUESTO DIFFERENTE APPEAL?



ENTITA' SEZIONI MIOTENDINEE



ANTERIORE



ANTEROLAT



POSTEROLAT



LATERALE



DEAMBULAZIONE PROTETTA

USO DEI BASTONI
E' ANCORA ATTUALE?





Worse patient-reported outcome after lateral approach than after anterior and posterolateral approach in primary hip arthroplasty

A cross-sectional questionnaire study of 1,476 patients 1–3 years after surgery

Einar Arnbø^a, Laili I. Havlin^{a,b}, Ørve Furnes^{a,b}, Vailborg Bastø^a, Lars Nordseth^a, Øystein Hovik^c, and Sighjorn Dimmen^{a,d}

^aUmsenhøgda University Hospital, Orthopaedic Department, Oslo; ^bDepartment of Clinical Medicine, University of Bergen; ^cThe Norwegian Arthroplasty Register, Department of Orthopaedic Surgery, Rykehuset University Hospital, Bergen; ^dNorwegian University of Health Sciences, Oslo, Norway

Correspondence: arnb@hio.no
Submitted 15.06.20; Accepted 14.08.13

Background — The surgical approach in total hip arthroplasty (THA) is often based on surgeon preference and local traditions. The anterior muscle-sparing approach has recently gained popularity in Europe. We tested the hypothesis that patient satisfaction, pain, function, and health-related quality of life (HRQoL) after THA is not related to the surgical approach.

Patients — 1,476 patients identified through the Norwegian Arthroplasty Register were sent questionnaires 1–3 years after undergoing THA in the period from January 2008 to June 2010. Patient-reported outcome measures (PROMs) included the hip disability osteoarthritis outcome score (HOOS), the Western Ontario and MacMaster Universities osteoarthritis index (WOMAC), health-related quality of life (EQ-5D-3L), visual analog scales (VAS) addressing pain and satisfaction, and questions about complications. 1,273 patients completed the questionnaire and were included in the analysis.

Results — Adjusted HOOS scores for pain, other symptoms, activities of daily living (ADL), sport/recreation, and quality of life were significantly worse ($p < 0.001$ to $p < 0.005$) for the lateral approach than for the anterior approach and the posterolateral approach (mean differences: 3.2–5.6). These results were related to more patient-reported limping with the lateral approach than with the anterior and posterolateral approaches (25% vs. 12% and 13%, respectively; $p < 0.001$).

Interpretation — Patients operated with the lateral approach reported worse outcomes 1–3 years after THA surgery. Self-reported limping occurred twice as often in patients who underwent THA with a lateral approach than in those who underwent THA with an anterior or posterolateral approach. There were no significant differences in patient-reported outcomes after THA between those who underwent THA with a posterolateral approach and those who underwent THA with an anterior approach.

The approach used for total hip arthroplasty (THA) is often based on the surgeon's preference and local traditions. In 2011, 7,360 primary THAs were reported to the Norwegian Arthroplasty Register (NAR) (Norwegian Arthroplasty Register Annual Report 2012). A lateral approach was used in 53% of the operations, the posterolateral approach in 20%, and an anterior approach in 16%. Anterior muscle-sparing approaches have gained popularity because it has been argued that patients with such surgical approaches have less pain, shorter length of stay, and shorter rehabilitation time. There are short-term effects (Rodriguez et al. 2014), and the long-term effects are not well documented.

The anterior approaches used in Norway are either a modified Smith-Petersen approach (Smith-Petersen 1949, Jødal and Jødal 1950) or an anterolateral Watson-Jones approach (Watson-Jones 1936). These may have a longer learning curve (Grevendans et al. 2013) and a higher incidence of early revision (Spanos et al. 2012, Langdon et al. 2012). The lateral approach (Harrington 1982) divides the anterior portion of gluteus medius and minimus. Muscular tendon rotator or osteotomy is used to convert the tendon into the trochanteric area. This approach has been blamed for increasing the risk of damage to the superior gluteal nerve and to the gluteus medius muscle (Gallie and Hogook 2006, Arthanson et al. 2007, Khan and Knowles 2007).

The posterolateral approach involves division of the perforans, obturator internus, and gemelli tendons (Ogilvie et al. 1990). This approach is considered to have less effect on gait since the abductor muscles are not divided (Shore 1991, Hallerud et al. 1993), but it has been associated with an increased risk of dislocations, with risk of injury to the sciatic nerve. More recent studies have shown that use of larger femoral head sizes can markedly reduce the dislocation rate (Andersson et al. 2010, Hansell et al. 2011, Ho et al. 2012).

VIA LATERALE IN ITALIA?



G.L.O.B.E.

2018

Report Annuale

REGISTRO ITALIANO ARTROPROTESI



o Italiano ArtroProtesi

Report
Annuale 2018



Tabella 2.6. Anca. Numero di interventi per caratteristiche dell'intervento chirurgico (lato operato, via di accesso) e per tipo di intervento

	Sostituzione totale				Sostituzione parziale		Revisione (*)		TOTALE	
	in elezione		in urgenza							
	N	%	N	%	N	%	N	%	N	%
Lato operato	23.034		3.015		7.915		1.795		35.759	
Destro	12.573	54,6	1.523	50,5	4.008	50,6	963	53,6	19.067	53,3
Sinistro	10.025	43,5	1.488	49,4	3.889	49,1	824	45,9	16.226	45,4
Bilaterale	436	1,9	4	0,1	18	0,2	8	0,4	466	1,3
Via di accesso	23.034		3.015		7.915		1.795		35.759	
Anteriore	3.992	17,3	155	5,1	346	4,4	112	6,2	4.605	12,9
Antero-Laterale	2.385	10,4	590	19,6	1.696	21,4	250	13,9	4.921	13,8
Laterale	4.293	18,6	921	30,5	2.743	34,7	465	25,9	8.422	23,6
Postero-Laterale	12.083	52,5	1.342	44,5	3.113	39,3	957	53,3	17.495	48,9
Altro	281	1,2	7	0,2	17	0,2	11	0,6	316	0,9

(*) Interventi di revisione totale o parziale, rimozione della protesi, conversione da endoprotesi ad artroprotesi, sostituzione spaziatore

Nota: alcuni dati potrebbero essere frutto di errori di codifica, come nel caso dell'intervento di protesi parziale che non prevede l'impianto del cotile


LA VIA LATERALE DIRETTA: E' ANCORA ATTUALE?



in urgenza

Sostituzione
parziale

YES



NO

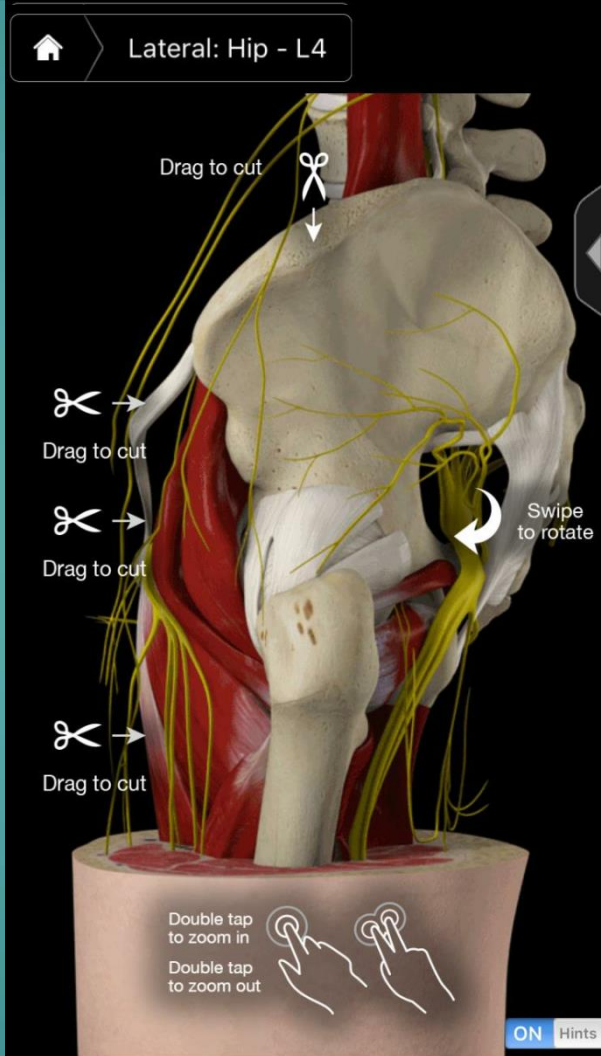
34

NO

PERCHE'?



PERCHE'?



SEMPlicita'?

HUNGERFORD 2000
MORE PRACTICAL AND APPEALING

Keep it simple...

PERCHE'?

RIDOTTO TASSO LUSSAZIONI PAI 1995



PIU' A RISCHIO SONO PROTESI SU FRATTURA

Tabella 2.6. Anca. Numero di interventi per caratteristiche dell'intervento chirurgico (lato operato e via di accesso) e per tipo di intervento

	1 Sostituzione totale		4 Sostituzione parziale		5 Revisione (*)		TOTALE	
	2 in elezione		3 in urgenza					
	N	%	N	%	N	%	N	%
Lato operato	23.034		3.015		7.915		1.795	35.759
Destro	12.573	54,6	1.523	50,5	4.008	50,6	963	53,6
Sinistro	10.025	43,5	1.488	49,4	3.889	49,1	824	45,9
Bilaterale	436	1,9	4	0,1	18	0,2	8	0,4
Via di accesso	23.034		3.015		7.915		1.795	35.759
Anteriore	3.992	17,3	155	5,1	346	4,4	112	6,2
Antero Laterale	2.385	10,4	590	19,6	1.696	21,4	250	13,9
Laterale	18,6		30,5		34,7		25,9	
Postero-Laterale	12.083	52,5	1.342	44,5	3.113	39,3	957	53,3
Altro	281	1,2	7	0,2	17	0,2	11	0,6

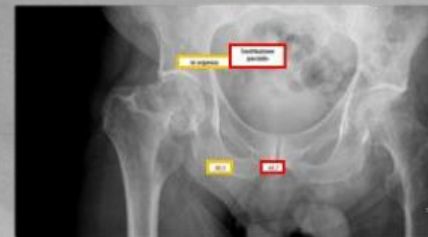(*) Interventi di revisione totale o parziale, rimozione della protesi, conversione da endoprotesi ad artroprotesi, sostituzione spaziatore

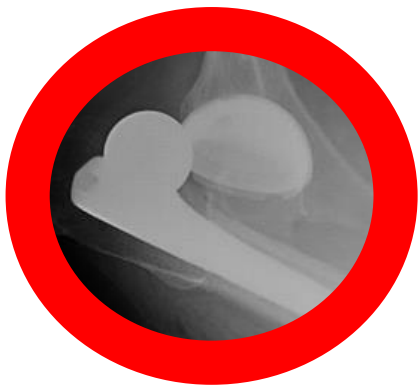
Nota: alcuni dati potrebbero essere frutto di errori di codifica, come nel caso dell'intervento di protesi parziale che non prevede l'impianto del cotile



Tabella 2.6. Anca. Numero di interventi per caratteristiche dell'intervento chirurgico (lato operato e via di accesso) e per tipo di intervento

	Sostituzione totale		Sostituzione parziale		Revisione (*)		TOTALE	
	in elezione		in urgenza					
	N	%	N	%	N	%	N	%
Lato operato	23.034		3.015		7.915		1.795	35.759
Destro	12.573	54,6	1.523	50,5	4.008	50,6	963	53,6
Sinistro	10.025	43,5	1.488	49,4	3.889	49,1	824	45,9
Bilaterale	436	1,9	4	0,1	18	0,2	8	0,4
Via di accesso	23.034		3.015		7.915		1.795	35.759
Anteriore	3.992	17,3	155	5,1	346	4,4	112	6,2
Antero Laterale	2.385	10,4	590	19,6	1.696	21,4	250	13,9
Laterale	18,6		30,5		34,7		25,9	
Postero-Laterale	12.083	52,5	1.342	44,5	3.113	39,3	957	53,3
Altro	281	1,2	7	0,2	17	0,2	11	0,6





INSTABILITA' PUO' ESSERE FATALE



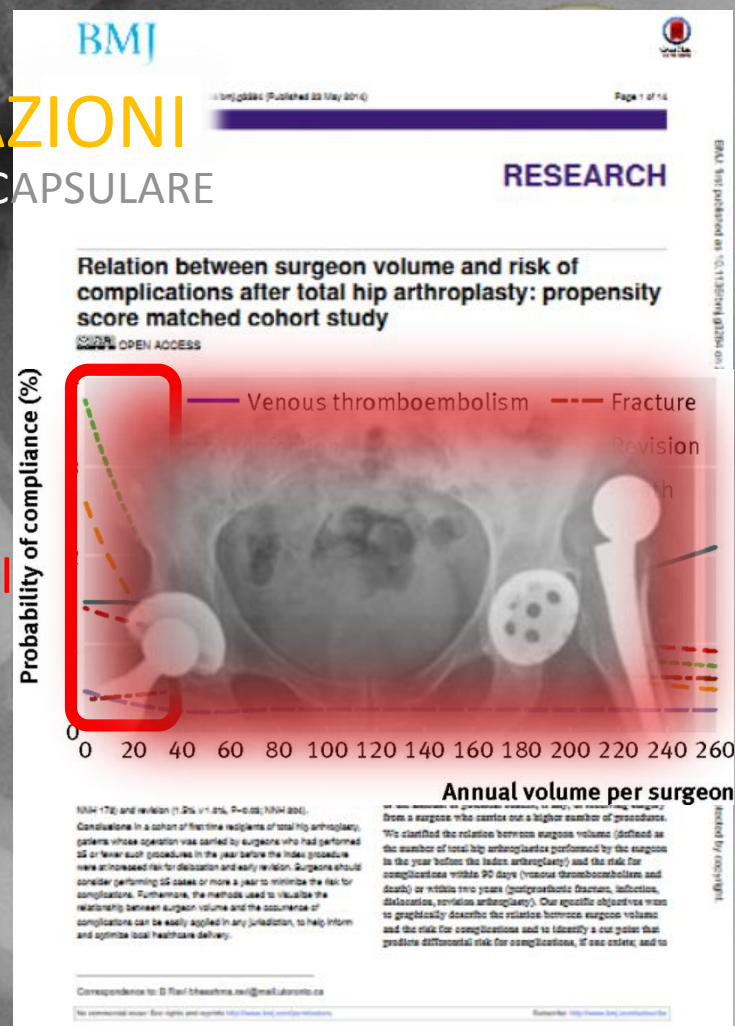
NECESSITA' AUSILI «TOLLERATA»?



PERCHE'? RIDOTTO TASSO LUSSAZIONI ANCHE IN ASSENZA DI RIPARAZIONE CAPSULARE

FORTE APPEAL PER PROTESIZZATORI OCCASIONALI

R





FORTE APPEAL PER PROTESIZZATORI OCCASIONALI

ALTISSIMO
VOLUME
PROTESI

ALTO
VOLUME
PROTESI

ALTO
VOLUME
PROTESI

Ruolo della scuola

EVOLUZIONE DELLA VIA LATERALE



ENTITA' SPLIT MUSCOLARE

DISTACCO MEDIO GLUTEO

EVOLUZIONE DELLA VIA LATERALE



36 V.S.Pai

Journal of Orthopaedics

Table 1
Various modification of McFarland and Osborne

	Hardinge ⁶	Learmonth ⁸	Mulliken ⁷	Pai
¹ G-V flap	1/2	Complete	1/3	1/3
² Proximal Extension from trochanter	NS		3 cm	3 cm
³ Anterior Osteotomy	—	—	—	—
⁴ Capsule	R/E	E	E/T-T	R
⁵ G-V flap Repair	T-T	T-B	T-T B-B B-B	T-B

¹ G-V flap(Gluteus-vastus): Width of the anterior flap in relation to width of the muscle

² Proximal extension of the glutei split from the tip of the greater trochanter:(NS = Not specified)

³ Anterior Osteotomy: Flap is elevated with a piece of trochanter

⁴ Capsule R/E = Retained or Excised

⁵ G-V flap repair: T-T = Tendon to tendon repair; T-B = Tendon (flap) to the bone with bone stitches; B-B = Bone to bone following trochanteric osteotomy

EVOLUZIONE DELLA VIA LATERALE



Table 1
Various modification of McFarland and Osborne lateral approach to the hip

	Hardinge ⁶	Learmonth ⁸	Mulliken ¹³	Dall ²	McLauchan ¹¹	Pai
¹ G-V flap	1/2	Complete	1/3	1/2	1/2	1/3
² Proximal Extension from trochanter	NS		3 cm	2 cm	NS	3 cm
³ Anterior Osteotomy	-		-	+	+	-
⁴ Capsule	R/E		E			R
⁵ G-V flap Repair	T		T-T			T-B

¹ G-V flap (Gluteus-vastus) flap: width of the anterior flap in relation to width of the incision

² Proximal extension of the gluteal split from the tip of the greater trochanter. (NS = Not specified)

³ Anterior Osteotomy: Flap is elevated with a piece of trochanter

⁴ Capsule R/E = Retained or Excised

⁵ G-V flap repair: T-T = Tendon to tendon repair; T-B = Tendon (flap) to the bone with bone stitches; B-B = Bone to bone following trochanteric osteotomy

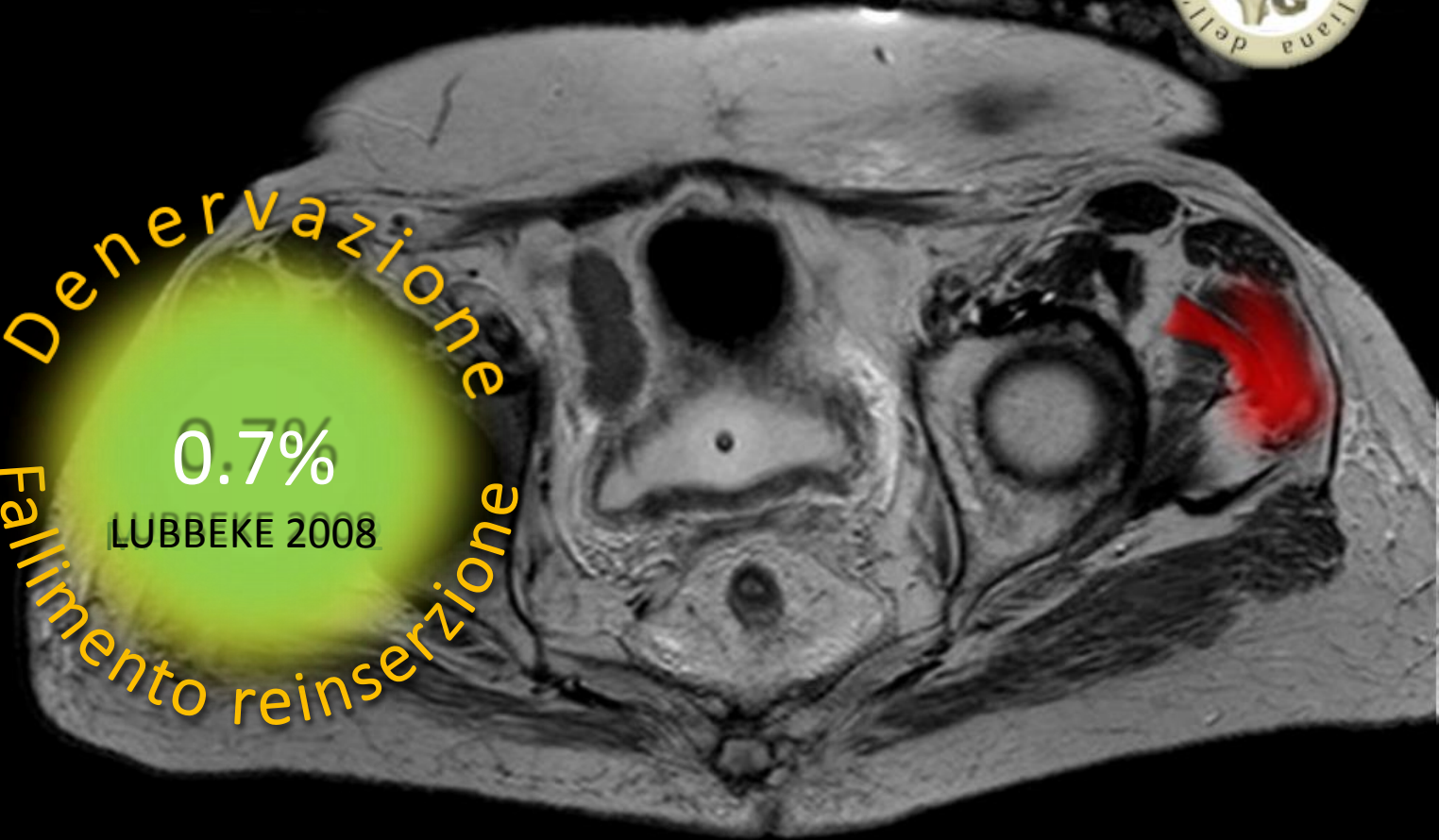
RIDURRE POSSIBILI COMPLICANZE



Denervazione
Fallimento reinserzione

0.7%

LUBBEKE 2008





8%

DOLORE SOGGETTIVO

14%

DOLORE EVOCABILE

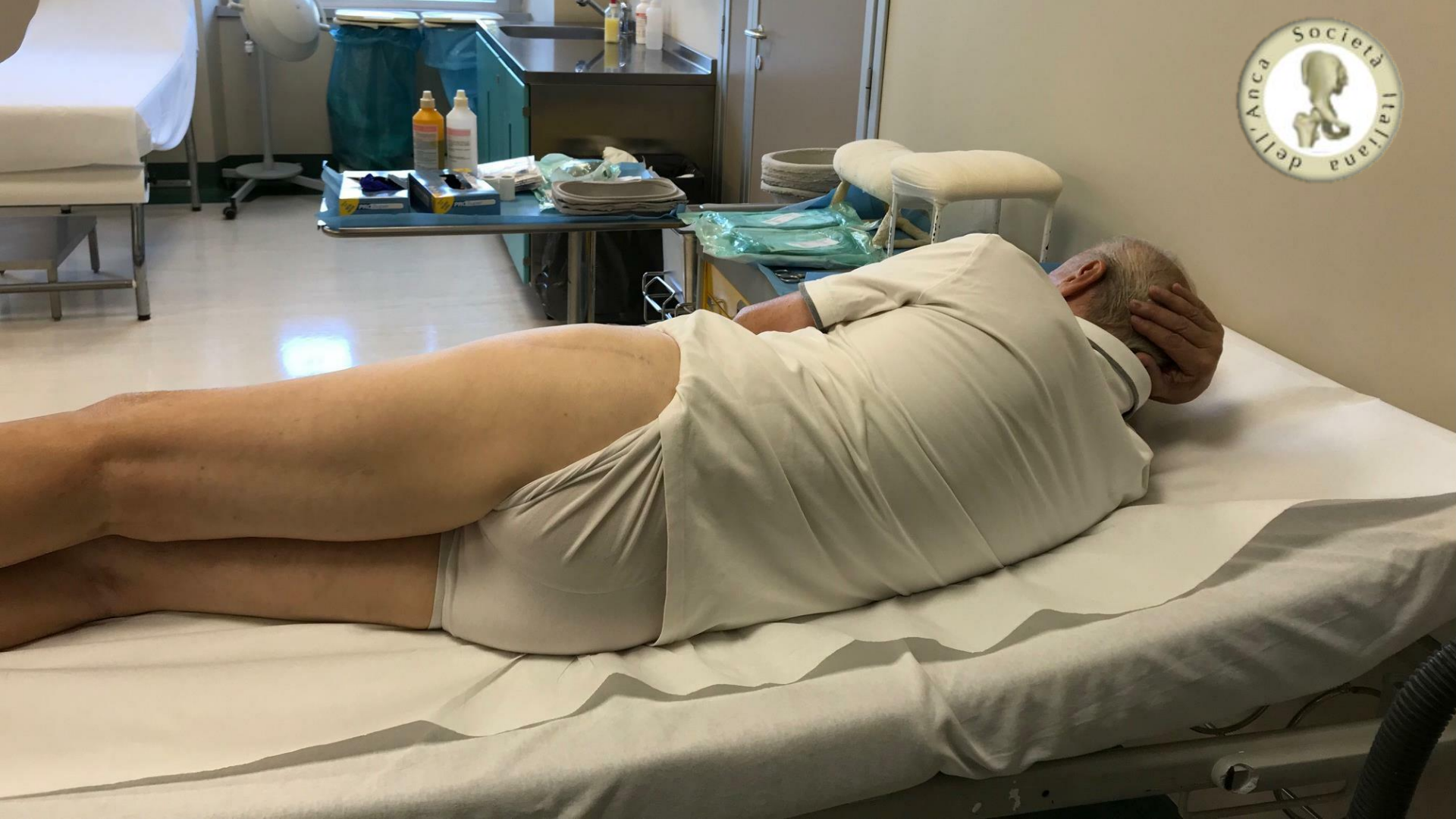0.7%

LUBBEKE 2008

4%

INSUFFICIENZA M.GLUTEO







CONGRESSO NAZIONALE DELLA
SOCIETÀ ITALIANA DELL'ANCA

19-20
settembre 2019
BERGAMO

CONFRONTO

ANTERIORE*

ANT-LAT

POST-LAT

GIOVEDÌ
19 SETTEMBRE 2019

GIOVEDÌ
19 SETTEMBRE 2019

Scelta impianto*
Piu' maneggevole
Learning curve
Più tollerante
Rischio lussazione inferiore

CONGRESSO NAZIONALE DELLA
SOCIETÀ ITALIANA DELL'ANCA



19-20
settembre 2019
BERGAMO

10.30 SIMPOSIO 1: LE VIE DI ACCESSO NELLE PROTESI PRIMARIE
12.00 (cont.)

11.05 La via di accesso anteriore
11.12

12.00 LINK & TENDERS
13.00 (vedi pagina 34)

12.00 WORKSHOP AZIENDALE
12.30 NORMEDITEC
(vedi pagina 34)

13.00 Lunch
13.30

SALA A

SALA B



GRAZIE



CONGRESSO NAZIONALE DELLA
SOCIETÀ ITALIANA DELL'ANCA

www.societaitalianadellanca.eu



19-20
settembre 2019

BERGAMO

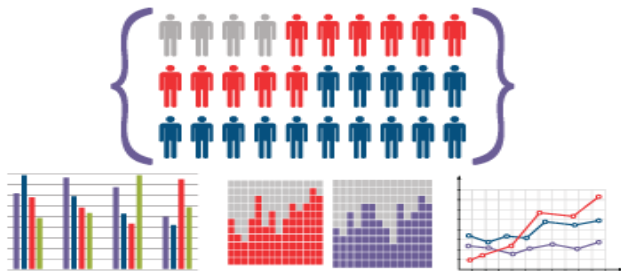
Presidente Onorario
Paolo Cherubino

Presidente
Claudio Carlo Castelli

PROGRAMMA



La letteratura e i registri: sopravvivenza, complicanze
e risultati a medio lungo termine
Emilio Romanini (Roma)



- Epidemiologia descrittiva
- Sopravvivenza
- PROMS
- Complicanze
- Riflessioni...

SUMMARY

Epidemiologia descrittiva

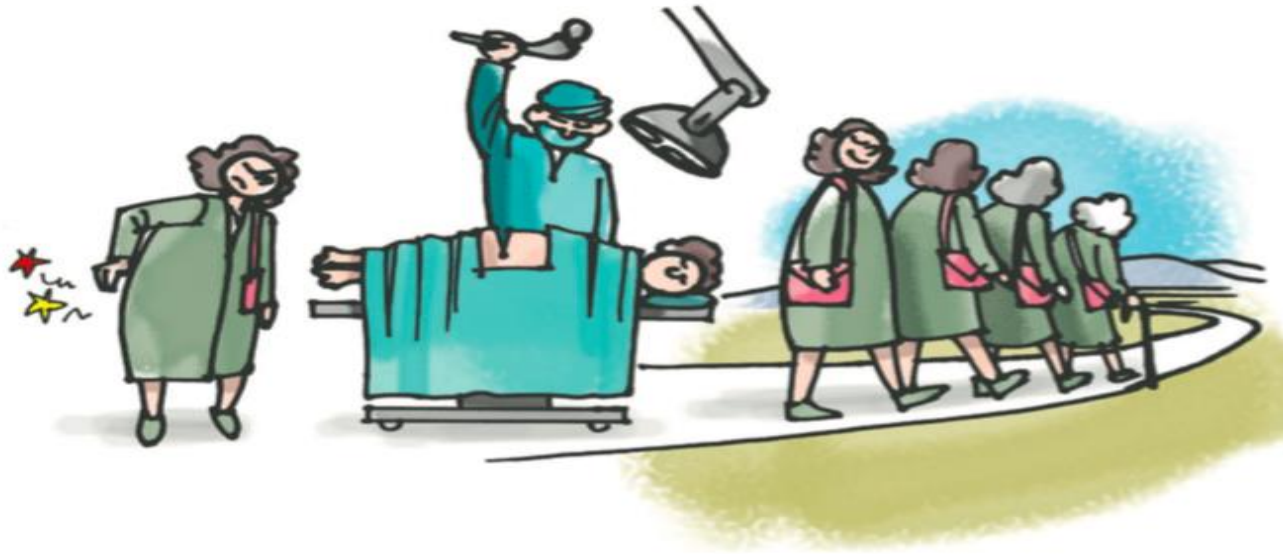

Tabella 2.6. Anca. Numero di interventi per caratteristiche dell'intervento chirurgico (lato operato e via di accesso) e per tipo di intervento

	Sostituzione totale				Sostituzione parziale		Revisione (*)		TOTALE	
	in elezione		in urgenza							
	N	%	N	%	N	%	N	%	N	%
Via di accesso	23.034		3.015		7.915		1.795		35.759	
Anteriore	3.992	17,3	155	5,1	346	4,4	112	6,2	4.605	12,9
Antero-Laterale	2.385	10,4	590	19,6	1.696	21,4	250	13,9	4.921	13,8
Laterale	4.293	18,6	921	30,5	2.743	34,7	465	25,9	8.422	23,6
Postero-Laterale	12.083	52,5	1.342	44,5	3.113	39,3	957	53,3	17.495	48,9
Altro	281	1,2	7	0,2	17	0,2	11	0,6	316	0,9

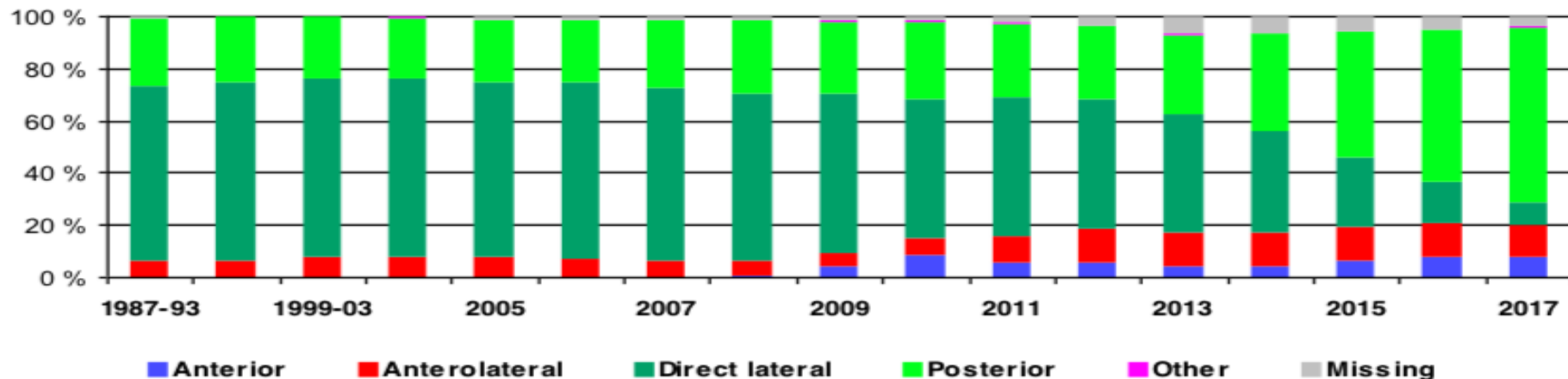


Table 9: In primary operations *

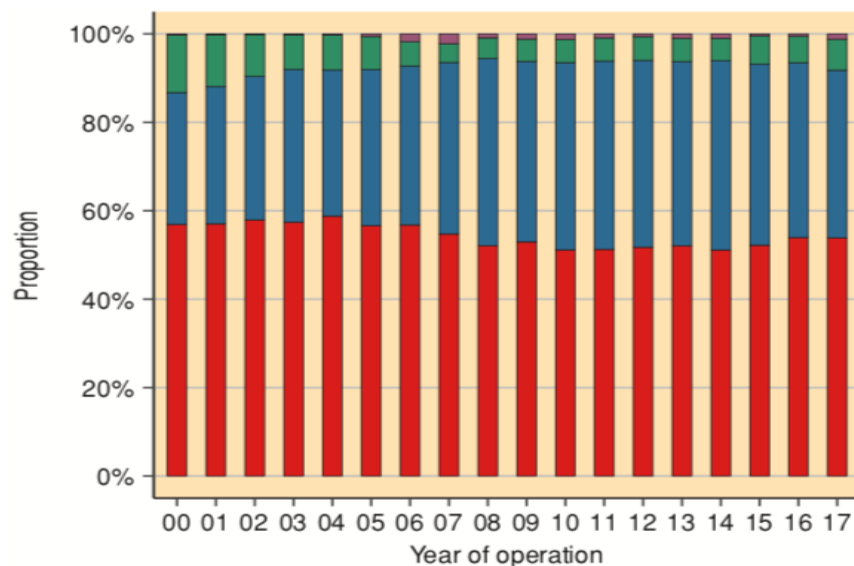
Year	Anterior	Anterolateral	Direct lateral	Posterior	Other	Missing information	Total
2017	692 (7,6 %)	1 162 (12,8 %)	743 (8,2 %)	6 139 (67,5 %)	5 (0,1 %)	356 (3,9 %)	9 097
2016	713 (8 %)	1 162 (13 %)	1 432 (16 %)	5 160 (57,8 %)	5 (0,1 %)	459 (5,1 %)	8 931
2015	520 (6,2 %)	1 147 (13,6 %)	2 234 (26,5 %)	4 080 (48,3 %)	3 (0 %)	458 (5,4 %)	8 442
2014	337 (4,1 %)	1 059 (13 %)	3 174 (39 %)	3 015 (37,1 %)	17 (0,2 %)	530 (6,5 %)	8 132
2013	342 (4,2 %)	1 081 (13,3 %)	3 626 (44,8 %)	2 472 (30,5 %)	24 (0,3 %)	553 (6,8 %)	8 098
2012	438 (5,6 %)	1 023 (13 %)	3 919 (49,9 %)	2 192 (27,9 %)	12 (0,2 %)	263 (3,4 %)	7 847
2011	429 (5,8 %)	748 (10,2 %)	3 897 (52,9 %)	2 081 (28,3 %)	30 (0,4 %)	175 (2,4 %)	7 360
2010	625 (8,5 %)	470 (6,4 %)	3 918 (53,5 %)	2 154 (29,4 %)	48 (0,7 %)	115 (1,6 %)	7 330
2009	326 (4,6 %)	340 (4,8 %)	4 357 (61,2 %)	1 963 (27,6 %)	11 (0,2 %)	118 (1,7 %)	7 115
2008	68 (1 %)	387 (5,7 %)	4 360 (63,7 %)	1 927 (28,1 %)	8 (0,1 %)	98 (1,4 %)	6 848
2007	14 (0,2 %)	404 (6,1 %)	4 417 (66,3 %)	1 711 (25,7 %)	10 (0,2 %)	104 (1,6 %)	6 660
2006	2 (0 %)	452 (7,2 %)	4 270 (67,6 %)	1 482 (23,5 %)	3 (0 %)	110 (1,7 %)	6 319
2005	7 (0,1 %)	521 (7,9 %)	4 419 (67 %)	1 534 (23,3 %)	4 (0,1 %)	112 (1,7 %)	6 597
2004	8 (0,1 %)	462 (7,4 %)	4 285 (68,9 %)	1 437 (23,1 %)	6 (0,1 %)	20 (0,3 %)	6 218
1999-03	52 (0,2 %)	2 312 (7,6 %)	0 925 (68,5 %)	7 112 (23,3 %)	36 (0,1 %)	113 (0,4 %)	30 550
1994-98	33 (0,1 %)	1 633 (6,5 %)	7 117 (68 %)	6 306 (25 %)	15 (0,1 %)	78 (0,3 %)	25 182
1987-93	104 (0,4 %)	1 853 (6,3 %)	9 632 (66,6 %)	7 628 (25,9 %)	25 (0,1 %)	240 (0,8 %)	29 482
Total	4 710 (2,5 %)	16 216 (8,5 %)	06 725 (56,1 %)	58 393 (30,7 %)	262 (0,1 %)	3 902 (2,1 %)	190 208

Number of primary total hip arthroplasties per type of surgical approach and year

2000–2017

Type of surgical approach	2000–2012	2013	2014	2015	2016	2017	Total ⁽¹⁾	% ⁽²⁾
Posterior approach in lateral position (Moore)	98 525	8 507	8 469	8 680	9 307	9 763	44 726	52.7
Direct lateral approach in lateral position (Gammer)	67 582	6 817	7 083	6 804	6 824	6 884	34 412	40.5
Direct lateral approach in supine position (Hardinge)	12 312	851	846	1 074	1 026	1 270	5 067	6.0
Other	1 536	170	163	71	95	192	691	0.8
(missing)	2 812	5	2	2	11	31	51	0.1
Total	182 767	16 350	16 563	16 631	17 263	18 140	84 947	100

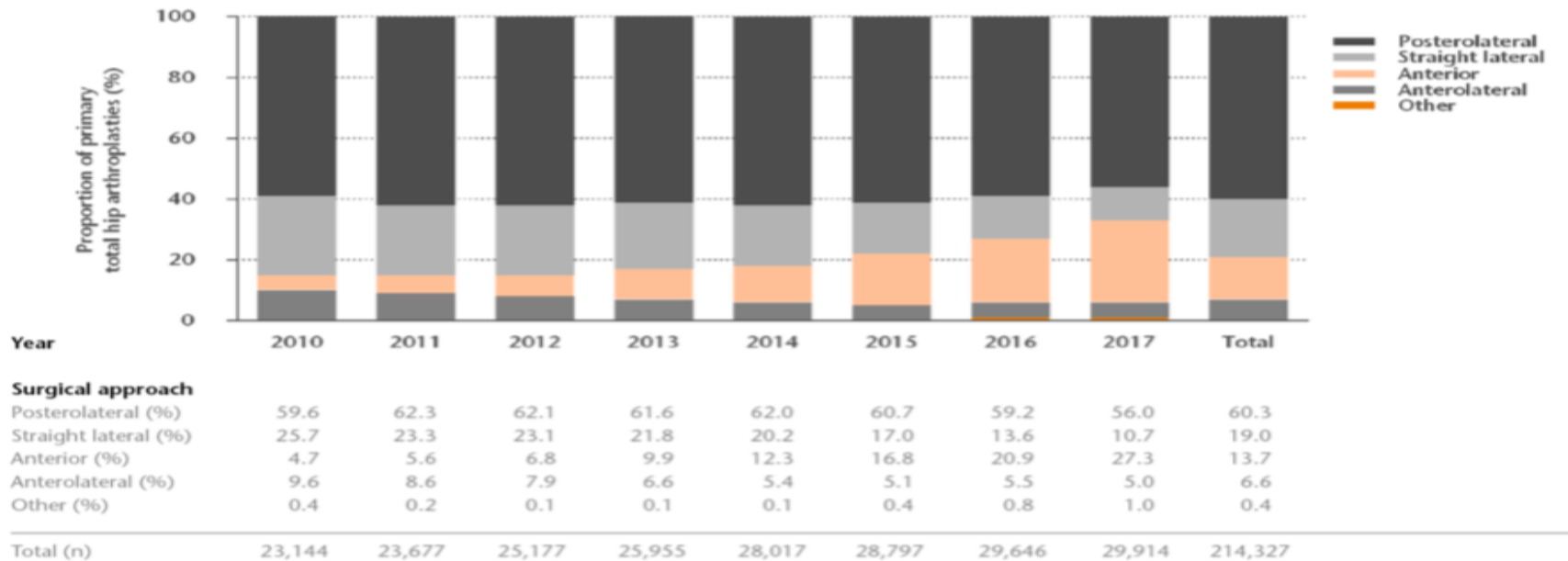
Copyright © 2018 Swedish Hip Arthroplasty Register



Copyright © 2018 Swedish Hip Arthroplasty Register

- Posterior
- Direct lateral (lateral position)
- Direct lateral (supine position)
- Others

FIGURE TREND (PROPORTION [%] PER YEAR) IN SURGICAL APPROACH FOR PERFORMING A PRIMARY TOTAL HIP ARTHROPLASTY IN THE NETHERLANDS IN 2010-2017.



© LROI August 2018

Swiss National Joint Registry

SIRIS Report 2012–2016

Annual Report of the Swiss National Joint Registry, Hip and Knee

Primary total hip arthroplasty: Surgical approach by year

Approach data only available from 2015 onwards

Surgical approach	2015		2016	
	N	%	N	%
Anterior	7193	41.6	7965	43.7
Anterolateral	5759	33.3	5976	32.8
Lateral	1442	8.3	1403	7.7
Posterior	2665	15.4	2739	15.0
Other approach	215	1.2	149	0.8
Total	17274	100	18232	100

Approach of revision of total hip arthroplasty

Data only available from 2015 onwards

Approach of revision	2015–2016	
	N	%
Posterior	1646	33.3
Lateral	1227	24.8
Anterolateral	868	17.6
Anterior	744	15.1
Transfemoral	250	5.1
Other approach	208	4.2

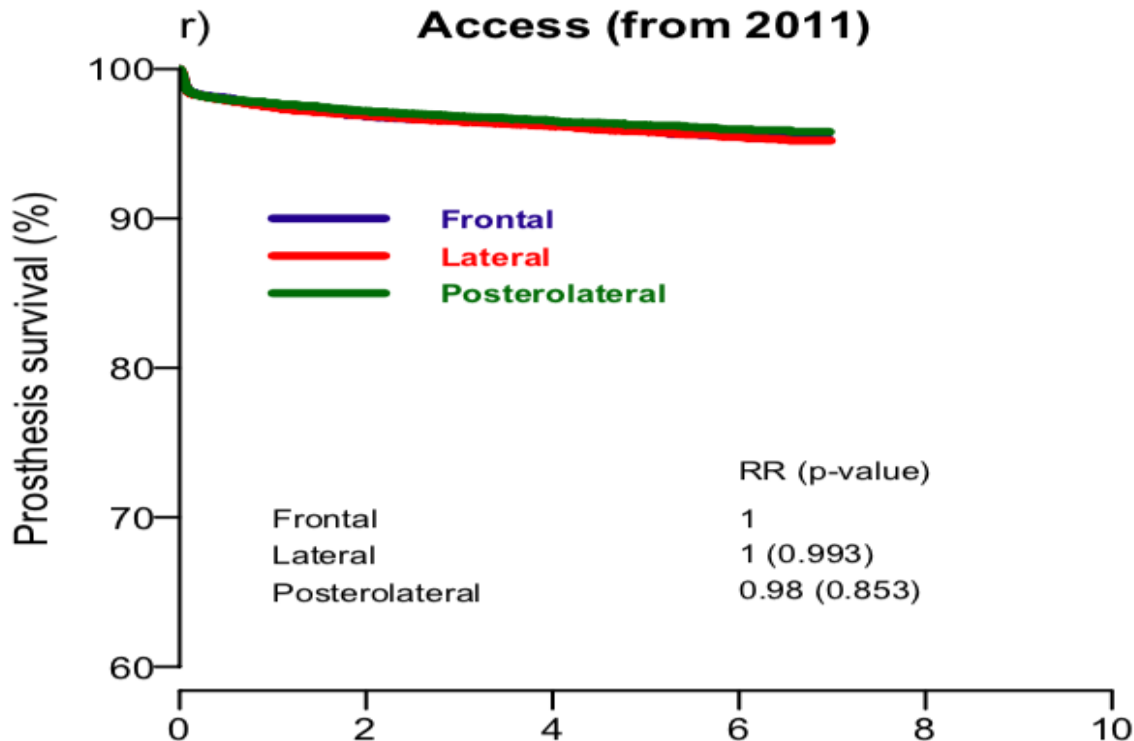
Sopravvivenza



Survival of total hip prosthesis, 2007-2017

REPORT

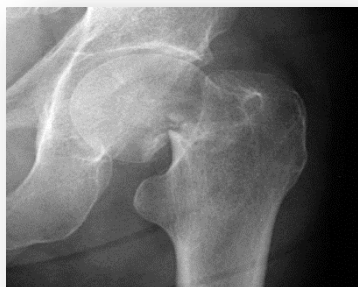June 2018



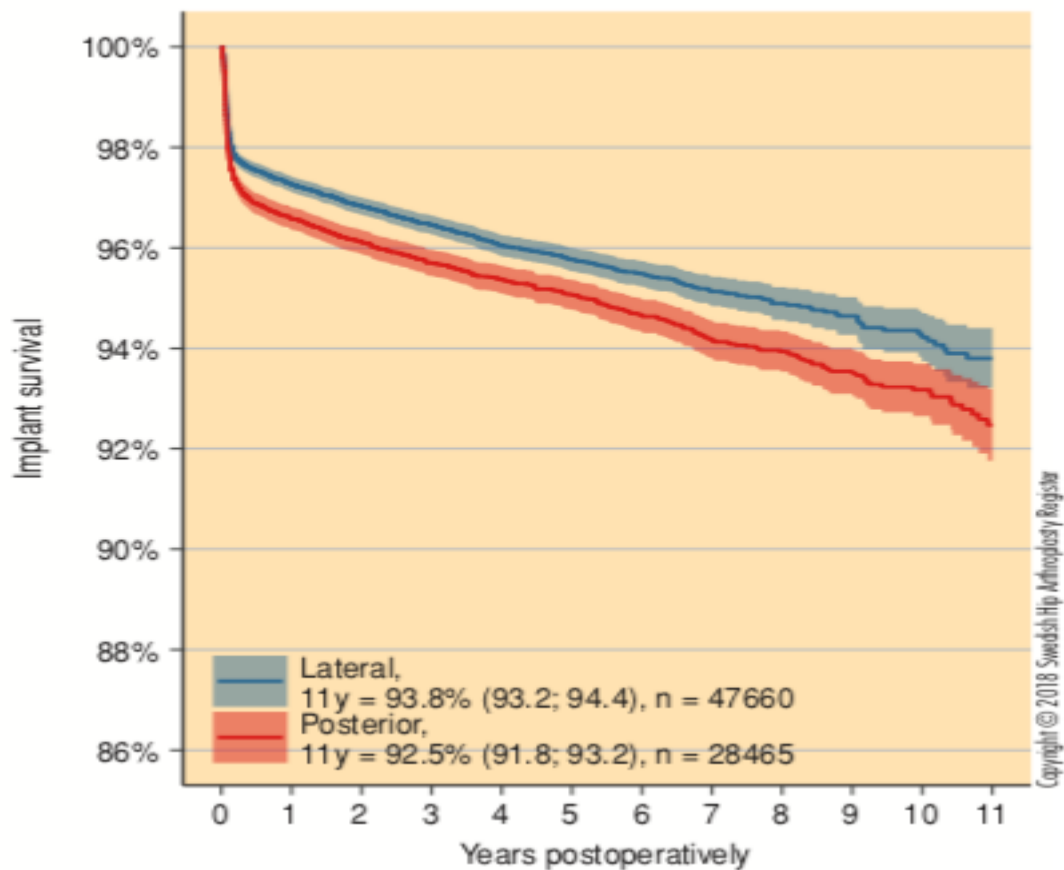
Demographics, fixation method and proportion of reoperated patients in relation to surgical approach

2000–2017

Surgical approach	Number	Proportion of women, %	Proportion of primary osteoarthritis, %	Proportion of operations with uncemented cup, %	Proportion of operations with uncemented stem, %	Proportion reoperated, %
Posterior approach in lateral position (Moore)	143 251	57.5	81.5	16.7	20.7	2.1
Direct lateral						
Lateral position (Gammer)	101 994	59.8	77.7	19.7	24.0	2.3
Supine position (Hardinge)	17 379	63.5	76.6	4.6	25.0	2.2
Mini-approach						
MIS/1-approach front	796	62.7	86.3	69.6	66.2	3.6
MIS/1-approach, back	415	53.7	76.9	48.9	53.7	2.7
MIS/2-approach	46	47.8	82.6	54.3	60.9	6.6
Watson-Jones (original)	479	53.7	77.5	44.7	56.8	2.5
Trochanter osteotomy						
Direct lateral	439	61.3	66.1	25.3	31.7	3.3
OCM-approach	52	30.8	92.3	90.4	94.2	1.9
No data	2 863	60.4	68.2	16.5	11.3	2.6



Implant survival – approach Fracture diagnosis and all revision causes 2005–2017



An international comparison of THA patients, implants, techniques, and survivorship in Sweden, Australia, and the United States

Elizabeth W PAXTON^{1,3}, Guy CAFRI¹, Szilard NEMES^{2,3}, Michelle LORIMER⁵, Johan KÄRRHOLM^{2,3,4}, Henrik MALCHAU^{2,3,4}, Stephen E GRAVES⁵, Robert S NAMBA⁶, and Ola ROLFSON^{2,3,4}

Surgical techniques

Although the posterior approach was used most frequently in all 3 countries, Sweden did not utilize the direct anterior approach. Several systematic reviews and registry studies suggest that the anterior approach is associated with lower dislocation and revision rates (Barrett et al. 2013, Higgins et al. 2015, Sheth et al. 2015, Miller et al. 2018a, b). However, these studies focused on short-term and functional outcomes without any certain conclusions concerning longer term revision rates. Despite differences in surgical approaches, Sweden had lower THA revision rates than the US cohort and Australia.

PROMS

WHEN WE WANT YOUR OPINION
WE'LL GIVE IT TO YOU





Orthopaedic registries with patient-reported outcome measures

Ian Wilson¹
Eric Bohm²
Anne Lübbeke³
Stephen Lyman⁴
Søren Overgaard⁵
Ola Rolfson⁶
Annette W-Dahl⁷
Mark Wilkinson⁸
Michael Dunbar⁹

- While revision surgery is the traditional endpoint of registries, it is blunt and likely insufficient as a measure of success; PROMs address this shortcoming by expanding beyond survival and measuring outcomes that are relevant to patients – relief of pain, restoration of function and improvement in quality of life.

Qualità di vita e protesi di anca

Emilio Romanini (a), Ciro Villani (b), Marina Torre (c)

(a) Gruppo di Lavoro Ortopedia Basata sulle prove d'Efficacia, Roma

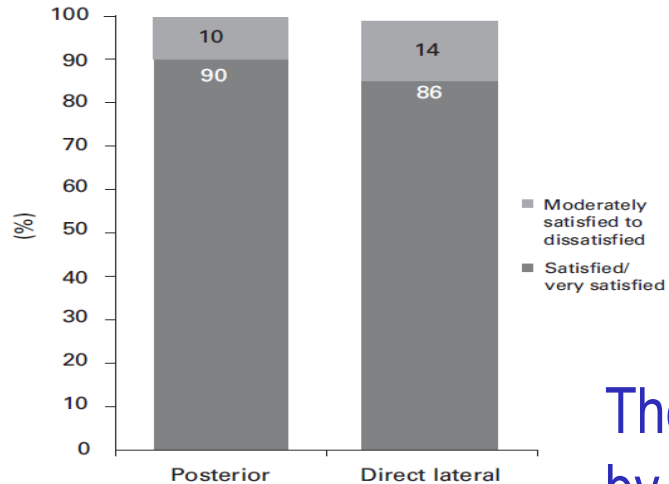
(b) Dipartimento di Scienze dell'Apparato Locomotore,

Università degli Studi di Roma "La Sapienza", Roma

(c) Centro Nazionale di Epidemiologia, Sorveglianza e Promozione della Salute,
Istituto Superiore di Sanità, Roma

Patient-reported outcome is influenced by surgical approach in total hip replacement

A STUDY OF THE SWEDISH HIP ARTHROPLASTY REGISTER INCLUDING 42 233 PATIENTS



The results indicate that some patients operated by the direct lateral approach report an inferior outcome compared with the posterior approach.

A Comparison of Surgical Approaches for Primary Hip Arthroplasty: A Cohort Study of Patient Reported Outcome Measures (PROMs) and Early Revision Using Linked National Databases



Simon S. Jameson, MRCS ^{a,b}, James Mason, DPhil, MSc BSc(Hons) ^a, Paul Baker, MSc, FRCS (Tr&Orth) ^{a,b}, Paul J. Gregg, FRCS, Ed (Orth) ^{a,b,c}, Ian A. McMurtry, FRCS, (Tr&Orth) ^{a,c}, David J. Deehan, MD, MSc, FRCS (Tr&Orth) ^{a,d}, Mike R. Reed, MD, FRCS(Tr&Orth) ^{a,e}

Patient Reported Outcomes for Populations Studied, by Surgical Approach.

	Cemented (Exeter V40/Contemporary Flanged 28 mm)			Cementless (Corail/Pinnacle MoM/CoC 36 mm)		
	Posterior	Lateral	P Value	Posterior	Lateral	P Value
Number (%)	1121 (57.9)	816 (42.1)		1266 (65.1)	678 (34.9)	
Oxford Hip scores						
Pre-operative, mean (sd, range)	18.9 (8.0, 0 to 44)	17.4 (7.8, 2 to 43)	<0.001	19.3 (8.1, 0 to 46)	18.6 (8.2, 1 to 42)	0.078
Post-operative, median (range)	42 (4 to 48)	39 (0 to 48)	<0.001	44 (2 to 48)	43 (5 to 48)	0.004
EQ5D visual analogue score						
Pre-operative, mean (sd, range)	68.7 (19.3, 4 to 100)	65.9 (20.2, 0 to 100)	0.003	66.8 (20.3, 0 to 100)	66.6 (21.0, 0 to 100)	0.848
Post-operative, mean (sd, range)	77.4 (16.7, 0 to 100)	73.0 (19.3, 0 to 100)	<0.001	78.5 (17.9, 0 to 100)	76.4 (17.6, 15 to 100)	0.015
EQ5D index						
Pre-operative, mean (sd, range)	0.393 (0.307, -0.358 to 1)	0.341 (0.313, -0.429 to 0.883)	<0.001	0.390 (0.316, -0.594 to 1)	0.377 (0.318, -0.239 to 1)	0.401
Post-operative, median (range)	0.815 (-0.003 to 1)	0.760 (-0.016 to 1)	<0.001	0.883 (-0.074 to 1)	0.812 (-0.077 to 1)	0.010
Satisfaction						
Excellent	454 (40.5)	249 (30.5)	<0.001	595 (47.0)	273 (40.3)	<0.001
Very good	395 (35.2)	290 (35.5)		442 (34.9)	228 (29.6)	
Good	212 (18.9)	192 (23.5)		160 (12.6)	121 (17.8)	
Fair	46 (4.1)	65 (8.0)		45 (3.6)	43 (6.3)	
Poor	14 (1.2)	20 (2.5)		25 (2.0)	13 (1.9)	
Success						
Much better	1003 (89.5)	669 (82.0)	<0.001	1136 (89.7)	584 (86.1)	0.131
A little better	86 (7.7)	102 (12.5)		81 (6.4)	60 (8.8)	
About the same	19 (1.7)	20 (2.5)		29 (2.3)	16 (2.4)	
A little worse	10 (0.9)	15 (1.8)		12 (1.5)	12 (1.8)	
Much worse	3 (0.3)	10 (1.2)		8 (1.0)	6 (0.9)	
Time from operation to PROMs completion, mean days (sd, range)	208.5 (28.2, 183 to 358)	209.0 (30.0, 183 to 363)	0.729	209.9 (30.3, 183 to 362)	208.7 (27.7, 183 to 343)	0.410



The posterior approach offered significantly better early functional outcome scores to patients.

Posterior approach compared to direct lateral approach resulted in better patient-reported outcome after hemiarthroplasty for femoral neck fracture

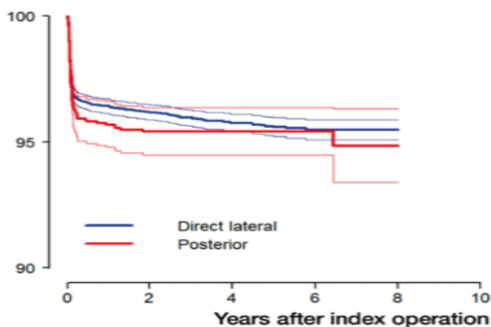
20,908 patients from the Norwegian Hip Fracture Register

Torbjørn B KRISTENSEN¹, Tarjei VINJE¹, Leif I HAVELIN^{1,2}, Lars B ENGESÆTER^{1,2}, and Jan-Erik GJERTSEN^{1,2}

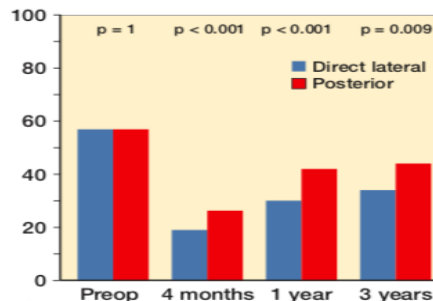


Hemiarthroplasty for hip fracture performed through a posterior rather than a direct lateral approach results in less pain, better patient satisfaction and better quality of life. The risk of reoperation was similar with both approaches.

Hemiarthroplasty survival (%)



No walking problems (%) all prostheses



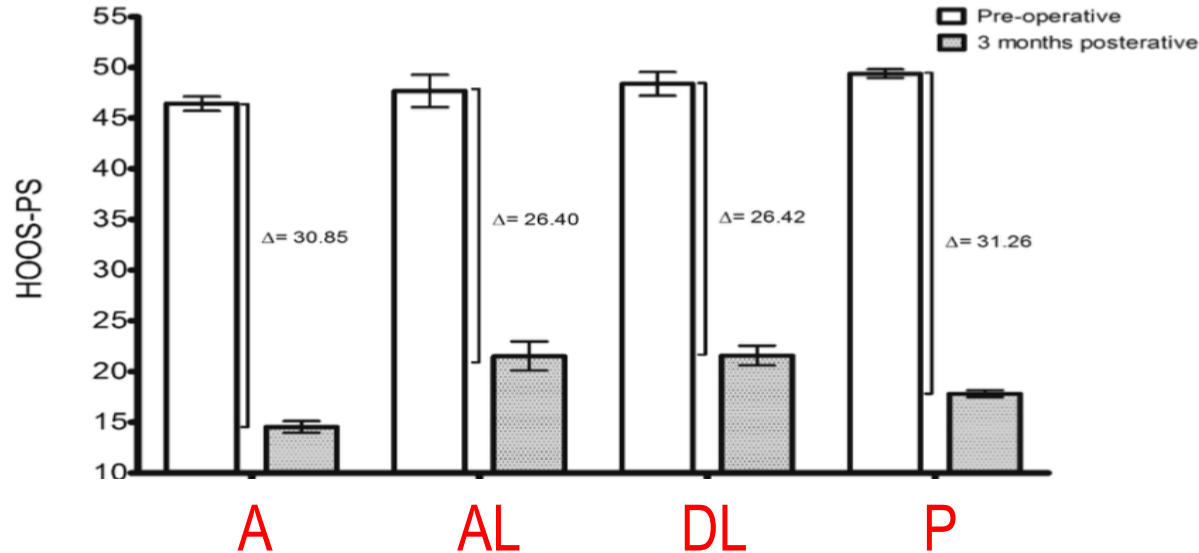
Scores	Unadj. mean values		Adj. mean values ^a		Direct lateral vs. Posterior		
	DLA	PA	DLA	PA	Adj. mean difference ^a	95% CI	p-value ^a
4 months							
Pain	22	20	25	23	2.2	0.53 to 3.8	0.01
Satisfaction	25	20	31	28	2.1	0.39 to 3.7	0.02
EQ-5D index score	0.55	0.57	0.45	0.47	-0.014	-0.034 to 0.008	0.2
EQ-VAS	60	61	52	53	-0.29	-2.1 to 1.5	0.8
12 months							
Pain	20	17	21	18	3.1	1.3 to 4.9	0.001
Satisfaction	25	21	27	22	4.7	2.7 to 6.7	< 0.001
EQ-5D index score	0.61	0.64	0.55	0.58	-0.030	-0.055 to -0.006	0.01
EQ-VAS	62	64	59	61	-2.1	-4.2 to -0.0	0.05
36 months							
Pain	20	16	20	17	3.1	0.41 to 5.9	0.02
Satisfaction	26	22	27	24	3.7	0.57 to 6.8	0.02
EQ-5D index score	0.61	0.66	0.56	0.60	-0.033	-0.070 to 0.004	0.08
EQ-VAS	61	65	60	63	-2.4	-5.6 to 0.80	0.1

Primary Arthroplasty

Similar Superior Patient-Reported Outcome Measures for Anterior and Posterolateral Approaches After Total Hip Arthroplasty
Postoperative Patient-Reported Outcome Measure Improvement After 3 months in 12,774 Primary Total Hip Arthroplasties Using the Anterior, Anterolateral, Straight Lateral, or Posterolateral Approach

Rinne M. Peters, MD ^{a, b, *}, Loes W.A.H. van Beers, MSc ^c, Liza N. van Steenberghe, MSc ^d, Julius Wolkenfelt, MD ^e, Harmen B. Ettema, MD, PhD ^e, Bas L.E.F. ten Have, MD ^f, Paul C. Rijk, MD, PhD ^a, Martin Stevens, PhD ^b, Sjoerd K. Bulstra, MD, PhD ^b, Rudolf W. Poolman ^c, Wierd P. Zijlstra ^a

DAA and PL showed more improvement in self-reported physical functioning (HOOS-PS) compared with AL and DAL in primary THA. *However, clinical differences were only small.*



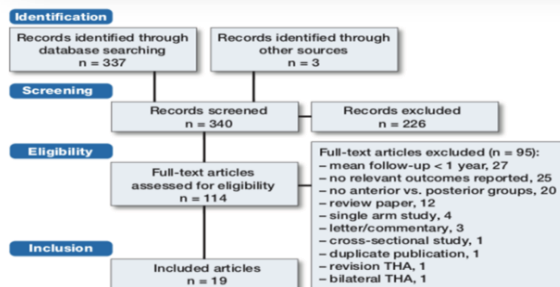
Complicanze



Influence of surgical approach on complication risk in primary total hip arthroplasty

Systematic review and meta-analysis

Larry E MILLER¹, Joseph S GONDUSKY², Atul F KAMATH³, Friedrich BOETTNER⁴, John WRIGHT⁵, and Samir BHATTACHARYYA⁵



Study	A	B	C	D	E	F	G
Comparative studies:							
Balasubramanian et al. 2016	●	●	●	●	●	●	●
Barrett et al. 2013	●	●	●	●	●	●	●
Batailler et al. 2017	●	●	●	●	●	●	●
Batailler et al. 2016	●	●	●	●	●	●	●
Fransen et al. 2016	●	●	●	●	●	●	●
Luo et al. 2016	●	●	●	●	●	●	●
Malek et al. 2016	●	●	●	●	●	●	●
Newman et al. 2016	●	●	●	●	●	●	●
Rathod et al. 2014	●	●	●	●	●	●	●
Rodriguez et al. 2014	●	●	●	●	●	●	●
Sugano et al. 2009	●	●	●	●	●	●	●
Taunton et al. 2009	●	●	●	●	●	●	●
Tripuraneni et al. 2016	●	●	●	●	●	●	●
Tsukada and Wakui 2015	●	●	●	●	●	●	●
Watts et al. 2015	●	●	●	●	●	●	●
Zhang et al. 2006	●	●	●	●	●	●	●
Registries							
Amie et al. 2014	●	●	●	●	●	●	●
Mjaaland et al. 2017	●	●	●	●	●	●	●
Sheth et al. 2015	●	●	●	●	●	●	●
Zijlstra et al. 2017	●	●	●	●	●	●	●

Study	Study design ^a	Treatment period	Parallel treatment period	Learning cases included	Mean follow-up, months	Sample size ^b	Mean age, years	Female, %	Mean BMI
					A	P	A	P	A
Comparative studies:									
Balasubramanian et al. 2016	RN	2006–2011	No	Yes	12	12	50	42	63
Barrett et al. 2013	RCT	2010–2011	Yes	No	12	12	43	44	61
Batailler et al. 2017	RN	2013–2015	Yes	Yes	14	14	211	101	72
Batailler et al. 2016	RN	2012	Yes	Yes	12	12	45	38	64
Fransen et al. 2016	RCT	2014	Yes	No	14	14	52	32	62
Luo et al. 2016	RN	2010–2014	Yes	No	18	18	265	183	71
Malek et al. 2016	RN	–	NR	NR	24	24	235	120	63
Newman et al. 2016	RN	2007–2011	No	No	16	30	286	293	62
Rathod et al. 2014	RN	2010	Yes	No	12	12	60	60	60
Rodriguez et al. 2014	RN	2006–2007	Yes	No	12	12	27	27	62
Sugano et al. 2009	RCT	2012	Yes	No	14	13	66	66	60
Taunton et al. 2009	RN	2012–2015	Yes	Yes	14	13	66	66	60
Tripuraneni et al. 2016	RN	2000–2009	No	NR	64	110	139	177	67
Tsukada and Wakui 2015	RN	2010–2014	NR	NR	12	12	716	3,040	64
Watts et al. 2015	RCT	2002–2004	Yes	Yes	20	20	60	60	61
Zhang et al. 2006	RN	2008–2010	Yes	No	24	30	421	421	67
Registries									
Amie et al. 2014	RN	2008–2013	Yes	Yes	52	52	2,017	5,961	67
Mjaaland et al. 2017	RN	2001–2011	No	Yes	36	36	1,851	3,147	65
Sheth et al. 2015	RN	2007–2015	No	Yes	40	40	14,446	100,823	68
Zijlstra et al. 2017	RN	–	–	–	–	–	–	–	–

A = anterior approach; P = posterior approach; NR = not reported.
^a Study design: PN = prospective nonrandomized; RCT = randomized controlled trial; RN = retrospective nonrandomized.
^b Reported as number of patients or hips.
^c All patients with BMI ≤ 27 kg/m².

Outcome	Comparative studies		Registries		p-value ^b
	Studies	Rate ratio (95% CI) ^a	Studies	Rate ratio (95% CI) ^a	
Infection	6	0.66 (0.16–2.7)	1	0.55 (0.37–0.80)	0.8
Thromboembolic event	4	0.59 (0.14–2.4)	0	–	–
Heterotopic ossification	3	0.58 (0.30–1.2)	1	0.81 (0.24–2.7)	0.6
Dislocation	8	0.55 (0.17–1.8)	3	0.74 (0.39–1.4)	0.7
Reoperation	12	1.03 (0.60–1.8)	4	0.83 (0.72–0.95)	0.5
Wound	5	0.93 (0.54–1.6)	0	–	–
Fracture	9	1.7 (0.79–3.7)	1	0.93 (0.66–1.3)	0.2
Patient-reported nerve injury	1	5.0 (0.24–104)	1	2.2 (1.2–4.3)	0.6

^a Rate ratio > 1 indicates higher complication incidence rate with anterior approach; RR < 1 indicates lower complication incidence rate with anterior approach.

^b Comparison of rate ratio in comparative studies versus registries, derived from Knapp–Hartung random effects meta-regression model.

Risk Factors for Intraoperative Periprosthetic Femoral Fractures During Primary Total Hip Arthroplasty. An Analysis From the National Joint Registry for England and Wales and the Isle of Man

Jonathan N. Lamb, BSc, MB BS ^{a, b, *}, Gulraj S. Matharu, MPhil, MRes, MB ChB ^{c, d}, Anthony Redmond, PhD, MSc, FFPM ^{a, e}, Andrew Judge, MSc, PhD ^{c, d}, Robert M. West, MSc, DPhil ^f, Hemant G. Pandit, DPhil, FRCS (Tr & Orth) ^{a, b, d, e}

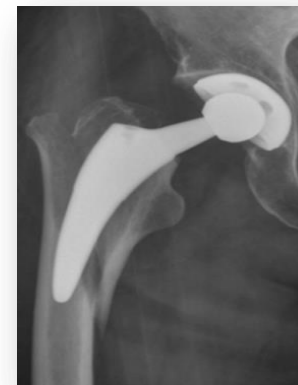

Table 4
Results From Multivariable Regression Demonstrating Risk Factors for IOPFF Subtypes.

	Relative Risk (95% Confidence Interval)		
	Calcar Cracks	Shaft Fractures	Trochanteric Fractures
Approach			
Posterior	1	1	1
Anterolateral	0.94 (0.87-1.02)	1.54 (1.23-1.93) ^a	1.36 (1.22-1.51) ^a
Trochanteric osteotomy	1.03 (0.51-2.05)	2.03 (0.51-8.16)	0.77 (0.29-2.05)
Other	0.83 (0.69-1.00)	2.06 (1.36-3.12) ^a	1.51 (1.21-1.89) ^a

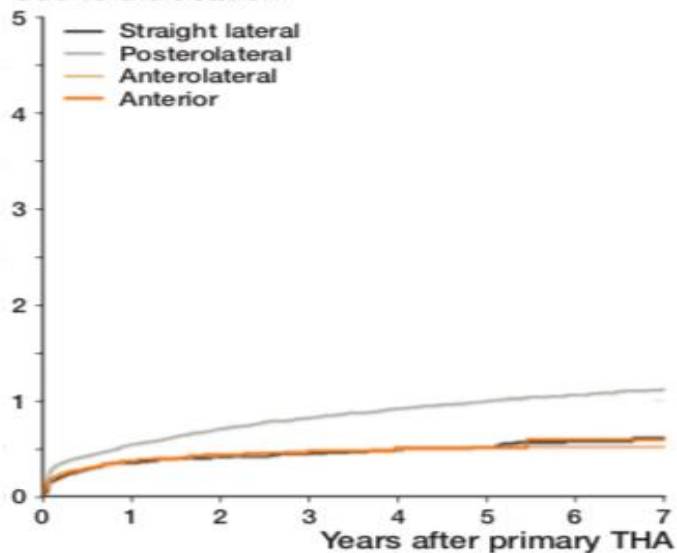
Effect of femoral head size and surgical approach on risk of revision for dislocation after total hip arthroplasty

An analysis of 166,231 procedures in the Dutch Arthroplasty Register (LROI)

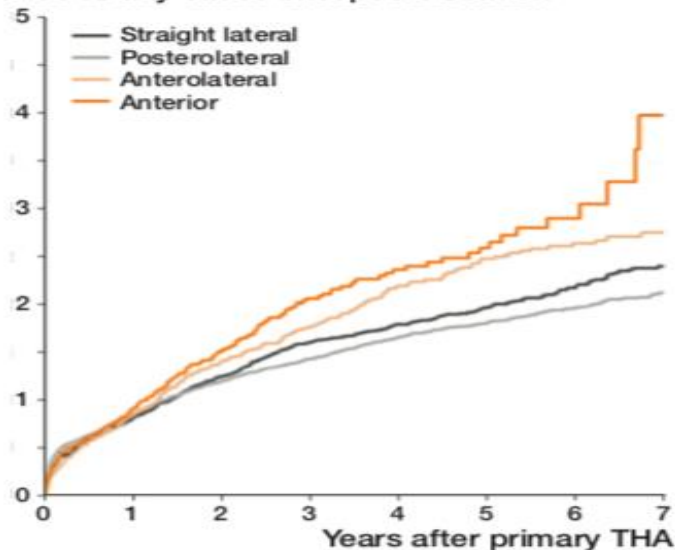
Wierd P ZIJLSTRA¹, Bas DE HARTOG¹, Liza N VAN STEENBERGEN², B Willem SCHEURS³,
and Rob G H H NELISSEN⁴



Cumulative revision percentage due to dislocation

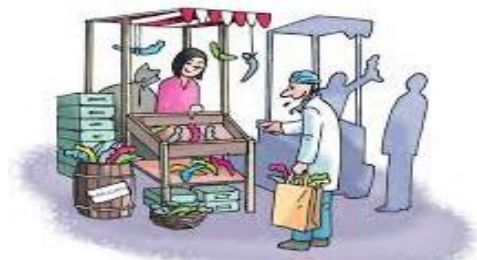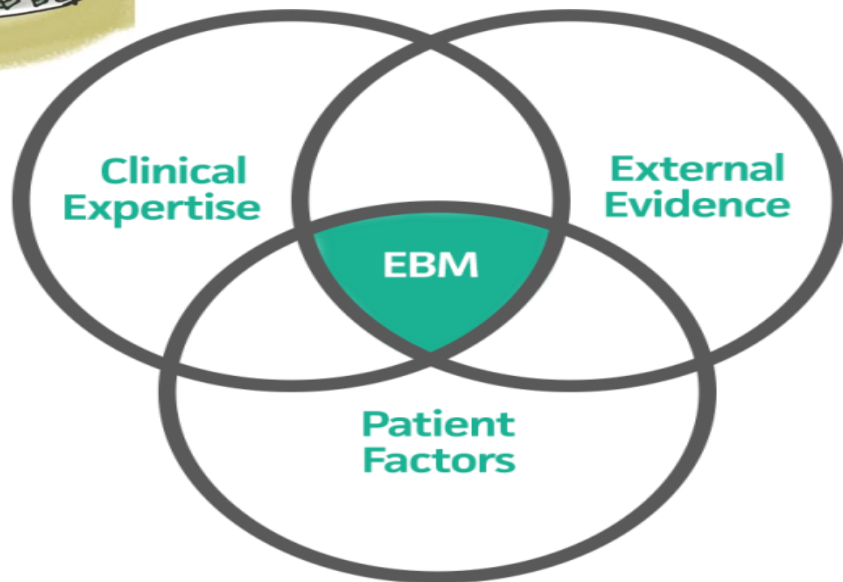


Cumulative revision percentage due to any cause except dislocation

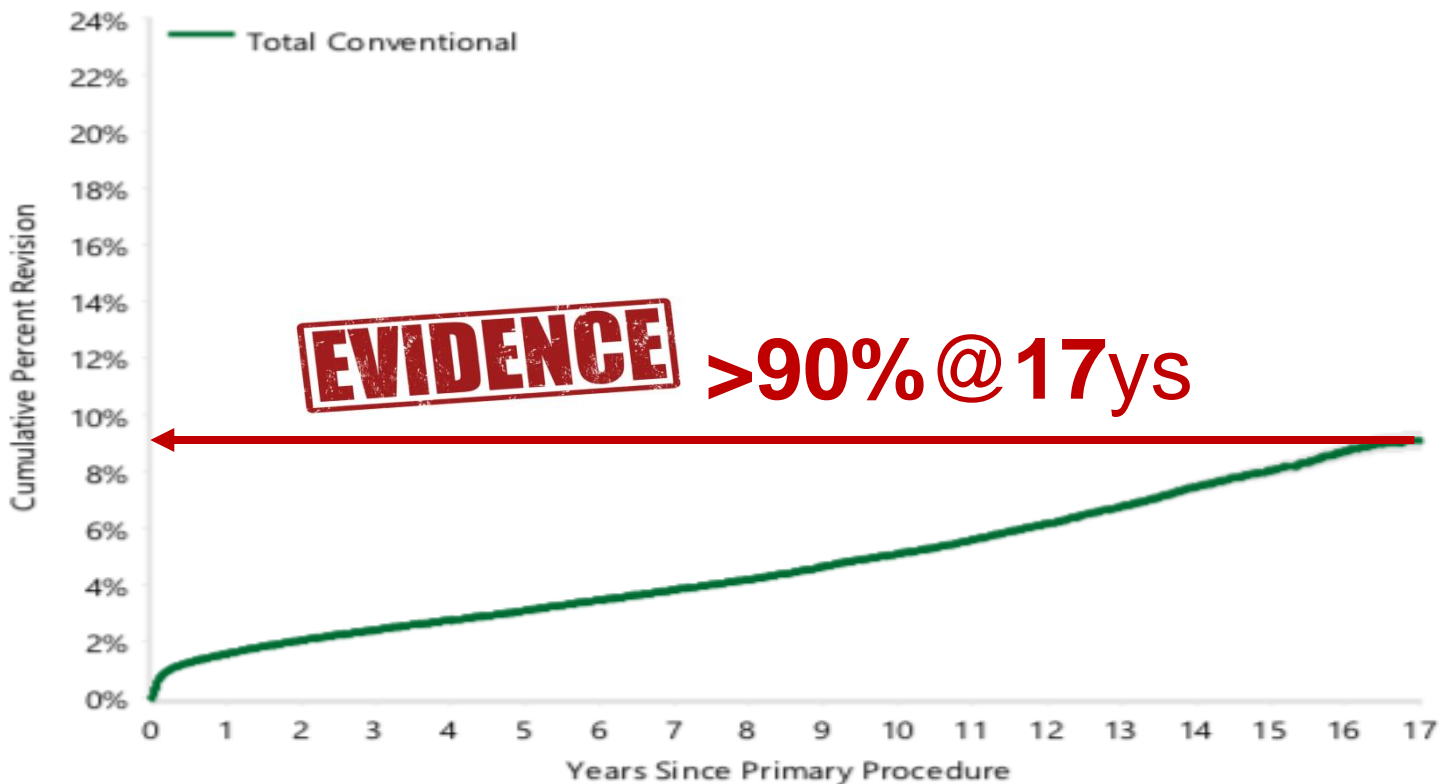


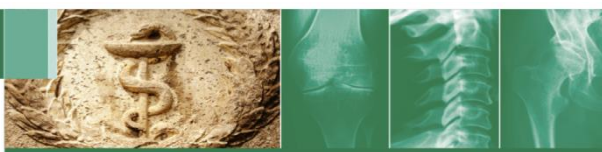


Riflessioni



Cumulative Percent Revision of Primary Total Conventional Hip Replacement (Primary Diagnosis OA)





Ethical orthopaedics for EFORT

"[...] set standards which reassure our patients and politicians that we uphold those ethical principles which should protect the trusting relationship between patient and doctor."

🐦 #EFORTethics



■ GENERAL ORTHOPAEDICS

Ethical standards for orthopaedic surgeons

We should offer **effective treatment**
based on the **best available evidence**



There should be an end to the haphazard way new surgical techniques and products are introduced. Patients may be attracted by the latest trend before it has been properly tried and evaluated. The history of Orthopaedics is littered with widely different procedures which have proved of little value.

Hip prosthesis introduction and early revision risk

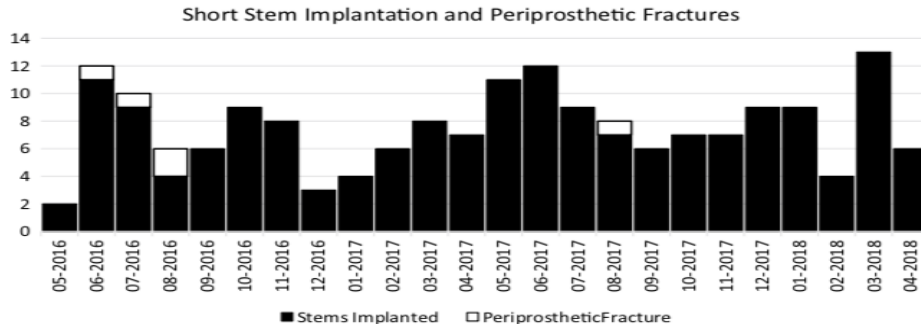
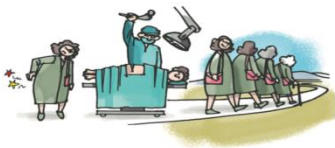A nationwide population-based study covering 39,125 operations

Mikko Peltola¹, Antti Malmivaara¹, and Mika Paavola^{1,2}

Ordinal number group Operation	No. of operations	No. of revisions	Unadjusted HR (95% CI)	Age- and sex-adjusted HR (95% CI)
<i>Minimum of stem and cup order numbers</i>				
1–15	5,967	228	1.3 (1.1–1.6)	1.3 (1.1–1.5)
16–30	3,980	123	1.1 (0.9–1.3)	1.1 (0.9–1.3)
31–50	4,185	135	1.1 (0.9–1.3)	1.1 (0.9–1.3)
51–100	6,820	220	1.1 (1.0–1.3)	1.1 (1.0–1.3)
101–	18,173	527	1.0	1.0

The **first 15 operations** with a new stem/cup model had an increased risk of early revision.

The risk of early revision at the implementation phase should be considered when a new type of THA is brought into use.



In this study, 80% of periprosthetic fractures following SS THA occurred within the **first 30 cases** for experienced arthroplasty-trained surgeons.

European Journal of Orthopaedic Surgery & Traumatology
<https://doi.org/10.1007/s00590-018-2355-z>

ORIGINAL ARTICLE • HIP • ARTHROPLASTY

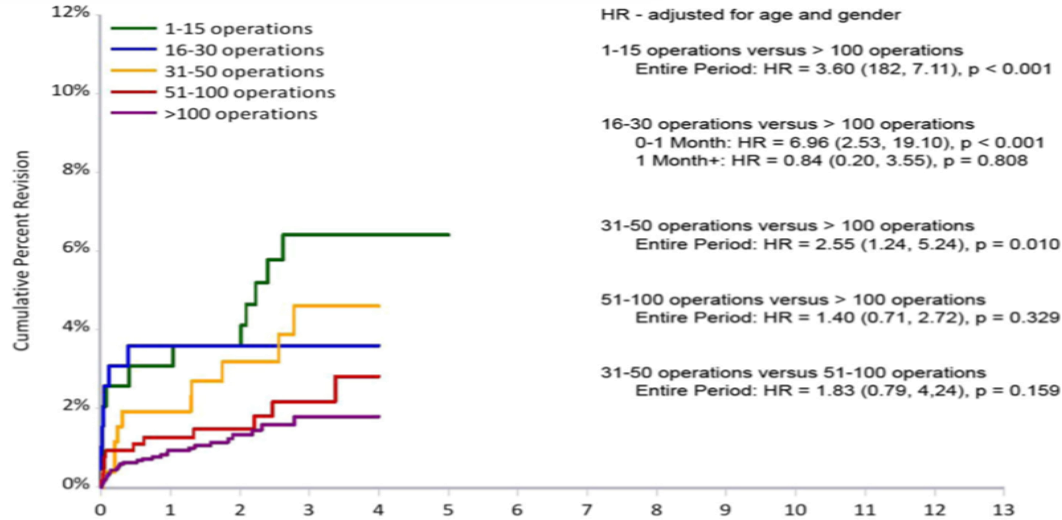


The learning curve following adoption of a novel short-stem prosthesis in total hip arthroplasty: implications on short-term patient outcomes

Jorge A. Padilla¹ · Afshin A. Anoushiravani² · James E. Feng¹ · Ran Schwarzkopf¹ · James Slover¹ · Scott Marwin¹

What Is the Learning Curve for the Anterior Approach for Total Hip Arthroplasty?

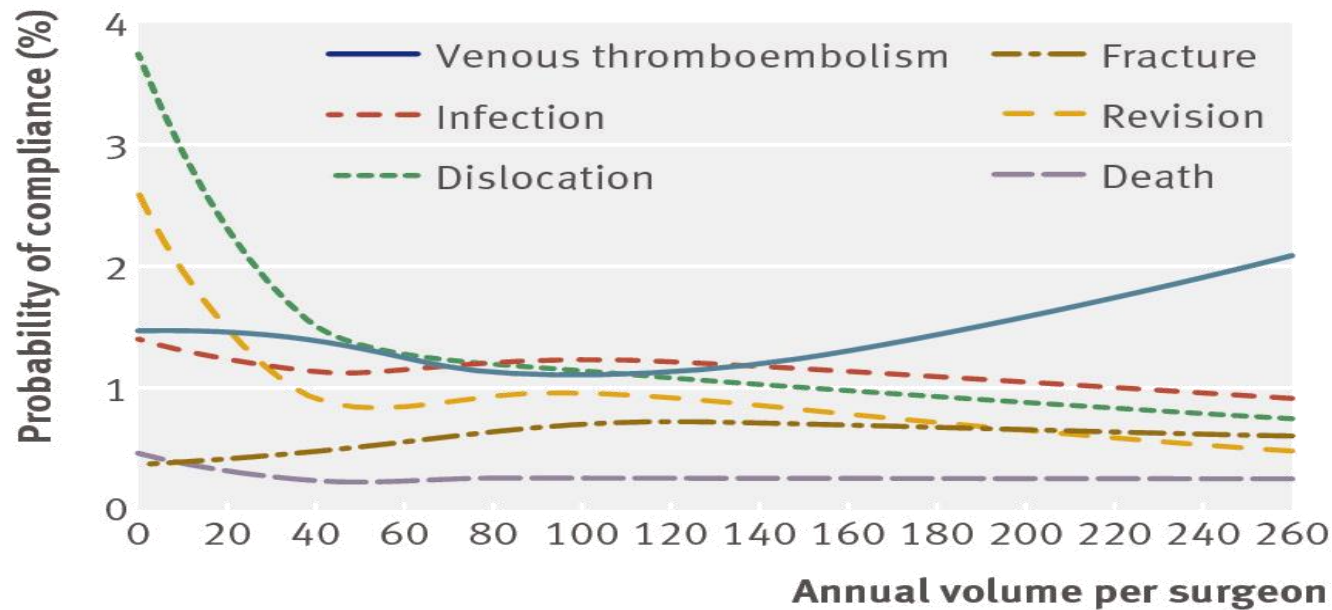
Richard Noel de Steiger MBBS, FRACS, Michelle Lorimer BSc(Math & Comp Sci) (Hons), Michael Solomon MBChB, FRACS



For surgeons who have performed >100 procedures, revision rate reduced from 6% for the first 15 procedures to 2% after first 100.

Relation between surgeon volume and risk of complications after total hip arthroplasty: propensity score matched cohort study

BMJ 2014 ; 348 doi: <http://dx.doi.org/10.1136/bmj.g3284> (Published 23 May 2014)



High annual surgeon volume reduces the risk of adverse events following primary total hip arthroplasty: a registry-based study of 12,100 cases in Western Sweden

Per JOLBÄCK^{1,2,3,5}, Ola ROLFSON^{1,3}, Peter CNUDE^{1,3,4}, Daniel ODIN³, Henrik MALCHAU^{1,3}, Hans LINDAHL^{1,2,3}, and Maziar MOHADDES^{1,3}

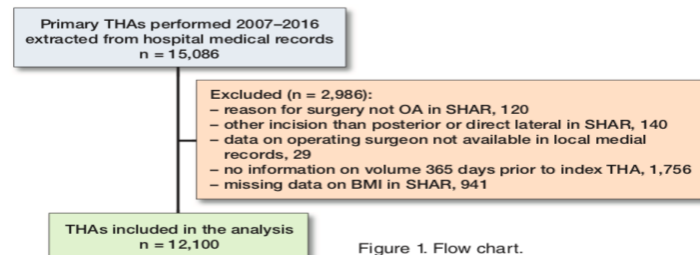


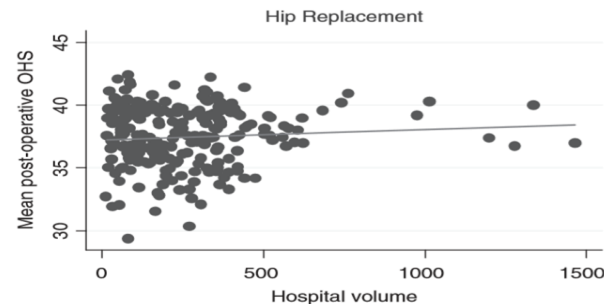
Figure 1. Flow chart.

Table 4. Predicted risk of AE within 90 days for annual surgeon volume of primary THAs

Annual surgeon volume	Mean risk (%)	95% prediction interval (%)
0	8	7–10
10	8	6–9
20	7	5–9
30	6	5–8
40	6	4–7
50	5	4–7

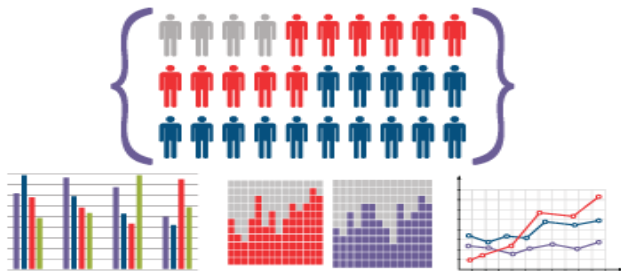
Relationship Between Patient-reported Outcomes of Elective Surgery and Hospital and Consultant Volume

Mira Varagunam, PhD, Andrew Hutchings, MSc, and Nick Black, MD



Consultant volume has an effect in hip replacement
on all 3 outcomes studied.

(A patient operated on by a consultant with an annual volume of 250. may achieve 1.2 points more on the OHS scale compared with patients treated by a consultant with a caseload of 50.)



- Early recovery (A)
- Patient satisfaction (A, P)
- Safety (less complications) ???
- Long term survival ?
- Learning curve (DL, P)
- ...

SUMMARY





artrogruppo.it

aloboweb.org